Anatomy of the saphenous nerve, its branches within the adductor canal, and its relationship with clinical implications during ACL reconstruction

Lampros Gousopoulos [1], Marc Barrera Uso [2]*, Ajit M Vakharia [3], Thomas Cucurulo [4], Emilie Peltier [5], Thais Dutra Vieira [2], Bertrand Sonnery-Cottet [2]

(*) Corresponding author: Marc Barrera Uso barrerauso@hotmail.com
1. Valais Hospital, Martigny, Switzerland
2. Centre Orthopedique Santy, 24 Avenue Paul Santy, Lyon 69008, France
3. University Hospitals Cleveland Medical Center, Case Western Reserve University, 11100 Euclid Avenue, Cleveland, USA 44106
4. Institut de Chirurgie Orthopédique et Sportive (ICOS 13), 463 rue Paradis 13008 Marseille. France
5. Service de chirurgie orthopédique pédiatrique APHM Hôpital La Timone Enfant 264 rue Saint Pierre 13005 Marseille, France

Purpose: The saphenous nerve lies in close proximity to the hamstrings and is at risk of injury during autologous grafting. This study aims to describe the potential risk of surgical injury to the saphenous branches during a classic HT harvesting with a stripper and to evaluate the efficacity of the diffusion of methylene blue infiltration into the adductor canal from a single retrograde injection from the hamstring tendon (HT) harvesting site.

Methods: Eighteen frozen cadaveric lower limbs from nine cadavers were selected for surgical dissection. The study was divided into two separate procedures:

1) Surgical dissection and detailed anatomic description of the saphenous nerve and its branches was performed.

2) Methylene blue infiltration was performed from the harvesting site of the hamstring tendons followed by dissection to evaluate the diffusion of methylene blue to the saphenous nerve and its branches.

Results: The direct visualization of the sartorial branch of the saphenous nerve (SBSN) was reproducible during HT harvesting, minimizing the risk of its iatrogenic damage.

Additionally, nine limbs were infiltrated with 20cc of methylene blue prior to dissection. The dissemination limits of the nine cadavers included the saphenous nerve and its two main branches, whether the division was in the adductor canal or downstream at the adductor hiatus, in all cases (100%). The upper limit of diffusion was located at an average of 17 cm from the medial tibial condyle, at the level of the fascia between the vastus medialis and the adductor longus muscle. The femoral vascular bundle, the saphenous nerve and the medial aspect of the vastus medialis were stained with methylene blue in all cases.

Conclusion: Direct visualization of the SBSN branch of the saphenous nerve, close to the HT expansions, must be recognized and appreciated to limit iatrogenic injury. Also, infiltration of the adductor canal via the hamstring donor site during autologous HT harvesting leads to diffusion to the saphenous nerve and its main branches which can be utilized intraoperatively with local anesthetic for reliable post operative pain control.

Level of Evidence: Level IV.

Keywords: ACL reconstruction, analgesia, FNB, postoperative pain, saphenous nerve, cadaver

Abbreviations

Lateral meniscus (LM); Medial meniscus (MM); Anterior cruciate ligament reconstruction (ACLR); Femoral nerve block (FNB); Adductor canal block (ACB); The infrapatellar branch of the saphenous (IPBSN); The sartorial branch (SBSN); Gracilis (GT); Bone-patellar tendon-bone (BPTB); Local infiltration analgesia (LIA); Semitendinosus (ST).

https://doi.org/10.70885/hmsj.2024.11.001

Introduction

Anterior cruciate ligament reconstruction (ACLR) remains one of the most common orthopaedic procedures [1][2][3][4][5]. Historically, the BPTB autograft was considered the gold standard for ACLR due to its excellent biomechanical strength [6]. However, hamstring autografts are gaining increasing popularity due to donor site morbidity associated with BPTB [7][8]. Because ACLR is minimally invasive and arthroscopically assisted, there is a trend towards performing this surgery on an outpatient basis [9][10]. Effective postoperative analgesia is essential in the ambulatory surgery setting, as it contributes to patient satisfaction, early discharge, and functional recovery [11][12][13][14]. In the inpatient setting, post operative pain after ACLR can potentially delay discharge and prolong hospital stay [13][15]. Faster recovery and better functional outcomes are observed when the patient's pain is well-controlled and opioid use is minimized [11][12][16][17].

Currently, there is no general consensus among surgeons or anesthesiologists regarding the optimal management of postoperative pain after ACLR, despite the wide variety of multimodal analgesia options available [13][14]. These options include regional nerve blocks such as femoral nerve block (FNB) or adductor canal block (ACB), performed preoperatively by anesthesiologists, or local instillation analgesia (LIA) performed intraoperatively by the surgeon. Due to the reduction in maximal voluntary isometric contraction of the quadriceps following FNB and the suboptimal postoperative analgesia it provides, a saphenous nerve block has been proposed as an alternative to avoid the negative impact on quadriceps motor function [17][18][19][20][21][22][23]. Nevertheless, this remains a delicate procedure with controversial results in the literature [24][25][26][27].

The anatomy of the saphenous nerve and its various branches in the adductor canal is complex [28][29][30][31][32][33][34][35][36]. Also, due to its anatomic proximity to the hamstring tendons, the senior author (BSC) has previously described a technique of intraoperative infiltration of the harvesting area with local anesthetics during ACLR which potentially reduces postoperative pain [37].

However; the proximity of the saphenous nerve to the gracilis (GT) and semitendinosus (ST) tendons may result in damage or sensory deficits due to lesions of the infrapatellar (IPBSN) and sartorial (SBSN) branches. This has been reported in 39% to 88% of patients after HT harvesting, likely being placed at risk or damaged during the passage of the tendon stripper [35][38][39][40][41]. Therefore, knowledge of the peri-hamstring neurovascular anatomy is crucial for a successful harvest with minimal postoperative morbidity.

The objective of our study was to evaluate 1) provide detailed anatomic description of the saphenous nerve through surgical dissection near the hamstring insertion site, and 2) the diffusion of methylene blue infiltration through the harvesting site of the hamstring tendons into the adductor canal to better assess diffusion ability intraoperatively with local anesthetic. For this purpose, we performed a cadaveric anatomical study of the saphenous nerve and its main branches and demonstrated its close proximity to the tibial HT insertion. We then studied the diffusion limits of a methylene blue infiltration through the usual hamstring tendon harvesting course. We hypothesized that infiltration of the hamstring tendon donor site during ACLR would allow the infiltrate to diffuse directly into the adductor canal and directly contact the saphenous nerve and its branches.

Materials and Methods

Eighteen frozen cadaveric lower limbs from nine cadavers were selected and used for surgical dissection. Authorization from the Faculty of Medicine and the Anatomy Department was obtained to carry out this cadaveric study. The median age of the donors was 75.3 years (range years); 5 were men and 4 women. The cadaveric limbs were placed in a supine position. The study was divided into two separate procedures. On one limb, a surgical dissection was performed with detailed recording of the anatomy. On the contralateral paired limb, an infiltration of methylene blue was first performed from the harvesting site of the hamstring tendons. Then the limb was fully dissected in order to evaluate the diffusion of the methylene blue to the saphenous nerve. In both procedures the relationship between hamstrings tendon and saphenous nerve along with its branches were analyzed to describe a reproducible technique for HT harvesting.

Descriptive general anatomy

The anatomical description of the adductor canal is complex and varies according to anatomical studies [31]. The adductor canal occupies the distal two-thirds of the medial aspect of the thigh and extends from the membrane between the adductor muscles and the vastus medialis proximally to the adductor hiatus distally. It is triangular in shape, bounded laterally by the vastus medialis, medially and anteriorly by the sartorius muscle (which forms the roof of the canal), and posteriorly by the adductor magnus. The femoral vessels and the saphenous nerve pass through this canal behind the sartorius muscle. In the distal aspect of the canal, a thick fascia extends between the vastus medialis and the adductor muscles, forming the anterior wall of the canal. This fascia should not be confused with the adductor hiatus, which is

located distally at the distal medial femoral supracondylar ridge where the femoral artery becomes the popliteal artery.

The saphenous nerve runs medially to the femoral artery and continues its descent through the adductor (Hunter's) canal, emerging from it by piercing a fascial layer between the sartorius and gracilis muscles. It becomes subcutaneous approximately 10 cm proximal to the knee. Distal to the adductor canal, the saphenous nerve divides into infrapatellar and sartorial terminal branches [31][33][36]. The infrapatellar branch of the saphenous nerve (IPBSN) pierces the sartorius muscle, after which it runs a superficial course and generally forms two branches [30][32]. Both branches cross the patellar tendon transversely to form the infrapatellar plexus. The IPBSN innervates the anteromedial aspect of the knee, the anterolateral aspect of the proximal part of the lower leg, and the anteroinferior part of the knee joint capsule [28][30][32][34][35]. Its injury usually results in numbness on the anterior aspect of the knee and the proximal lateral part of the lower leg.

The sartorial branch of the saphenous nerve (SBSN) courses longitudinally at the posteromedial aspect of the knee deep to the sartorius before becoming subcutaneous posterior to the medial femoral epicondyle by piercing the fascia between the sartorius and gracilis tendons. The sartorial branch then continues distally with the long saphenous vein to provide sensation to the medial aspect of the lower leg and ankle [29][31]. At the level of the meniscus, the sartorial branch of the saphenous nerve will rarely be encountered posterior to the semitendinosus with the knee in full extension. This should be kept in mind during both inside-out and outside-in techniques of medial meniscal repair [42].

I. Dissection of the first lower limb: anatomical study

The knee was placed at 20° of flexion and in external rotation to allow dissection of the femoral and saphenous nerves on the medial aspect of the thigh and knee. The dissection of the limb was performed from the root of the limb to the medial tibial condyle.

The vastus medialis and the femoral vascular bundles were exposed, and the sartorius muscle was retracted in order to expose the adductor canal. The adductor canal was then opened.

The origin of the saphenous nerve at the level of the femoral nerve (proximal third of the thigh) was exposed, as well as its course along the femoral vascular bundles (**Figure 1**) up to the adductor canal and its division into two branches, the infrapatellar branch and the sartorial branch (**Figure 2 and 3**).

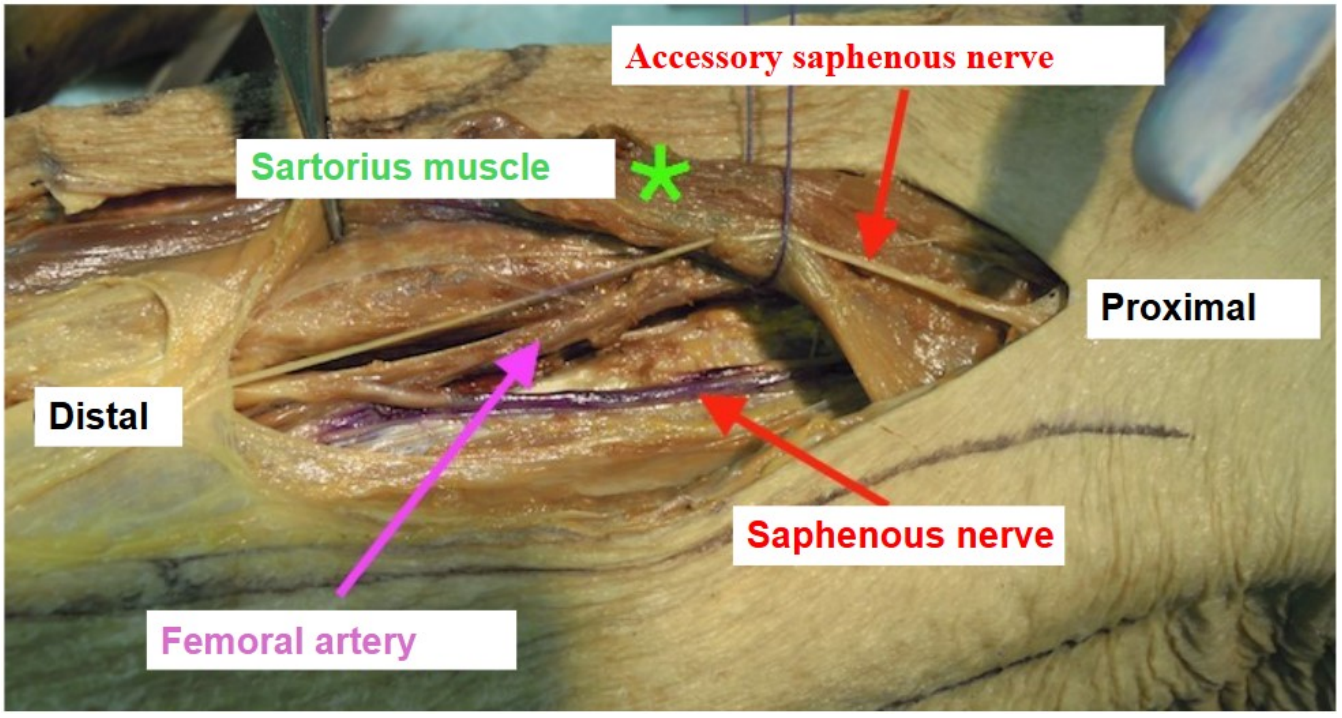

Figure 1: Saphenous vein in contact with the femoral artery upstream of the adductor canal. The red arrows indicate the saphenous nerve with the accessory saphenous nerve, the green asterisk shows the sartorius muscle, the purple arrow indicates the femoral artery.

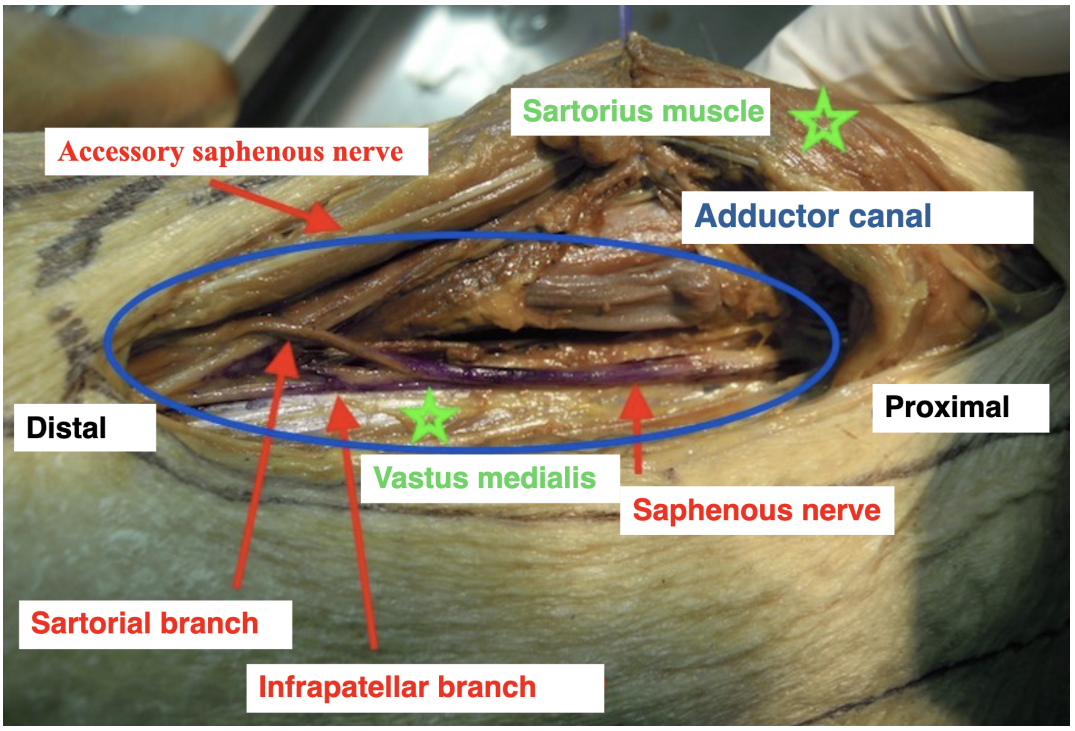

Figure 2: Anatomy of the adductor canal. The red arrows indicate the saphenous nerve and its branches, the bigger green star indicates the sartorius muscle, the smaller green star indicates the vastus medialis and the blue oval shape shows the adductor canal.

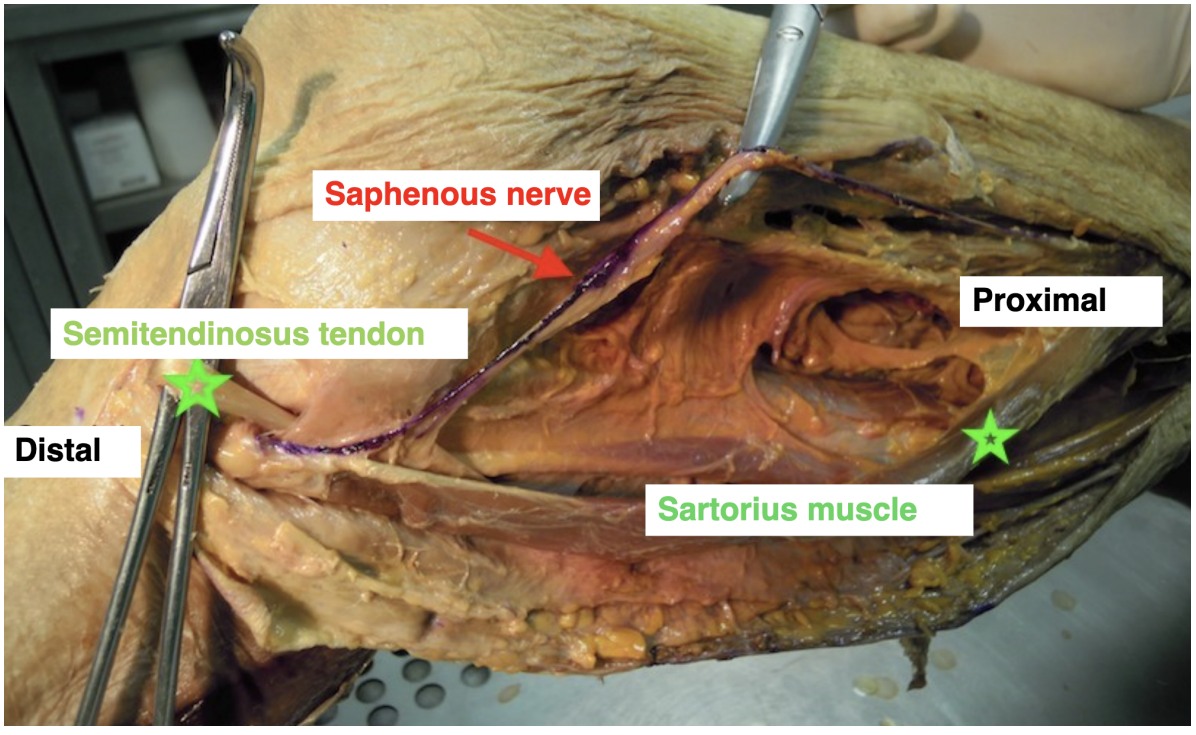

Figure 3: Relationship between the semitendinosus and the adductor canal. The red arrow indicates the saphenous nerve, the bigger green star indicates the semitendinosus tendon, the smaller green star indicates the sartorius muscle.

The accessory saphenous nerve which travels subcutaneously in contact with the long saphenous vein supplying infrapatellar branches downstream of the adductor canal was also dissected [43].

II. Contralateral limb: Study of the diffusion through the harvesting site of the semitendinosus

On the contralateral limb of the same cadaver, the knee was flexed to 90° in order to dissect the semitendinosus tendon using an anteromedial approach of the proximal tibia. The technique used was comparable to the typical technique of harvesting the hamstring tendon during a reconstruction of the anterior cruciate ligament as previously described [44].

Once the hamstring tendons were exposed as the level of the pes anserine, 20 cc of methylene blue infiltration was performed using a semi-rigid cannula under the sartorius fascia as shown in **Figure 4**. The limb was elevated in order to optimize the diffusion of the dye towards the root of the limb. **Figure 5** shows, as an example, the positioning of the infiltration cannula with prior dissection of the saphenous nerve. Dissection of the saphenous nerve was performed after the infiltration, in order to evaluate its diffusion in the adductor canal (**Figure 6**).



Figure 4: Placement of the trocar at the site of the semitendinosus harvest and Methylene Blue Infiltration of the Sample Site.

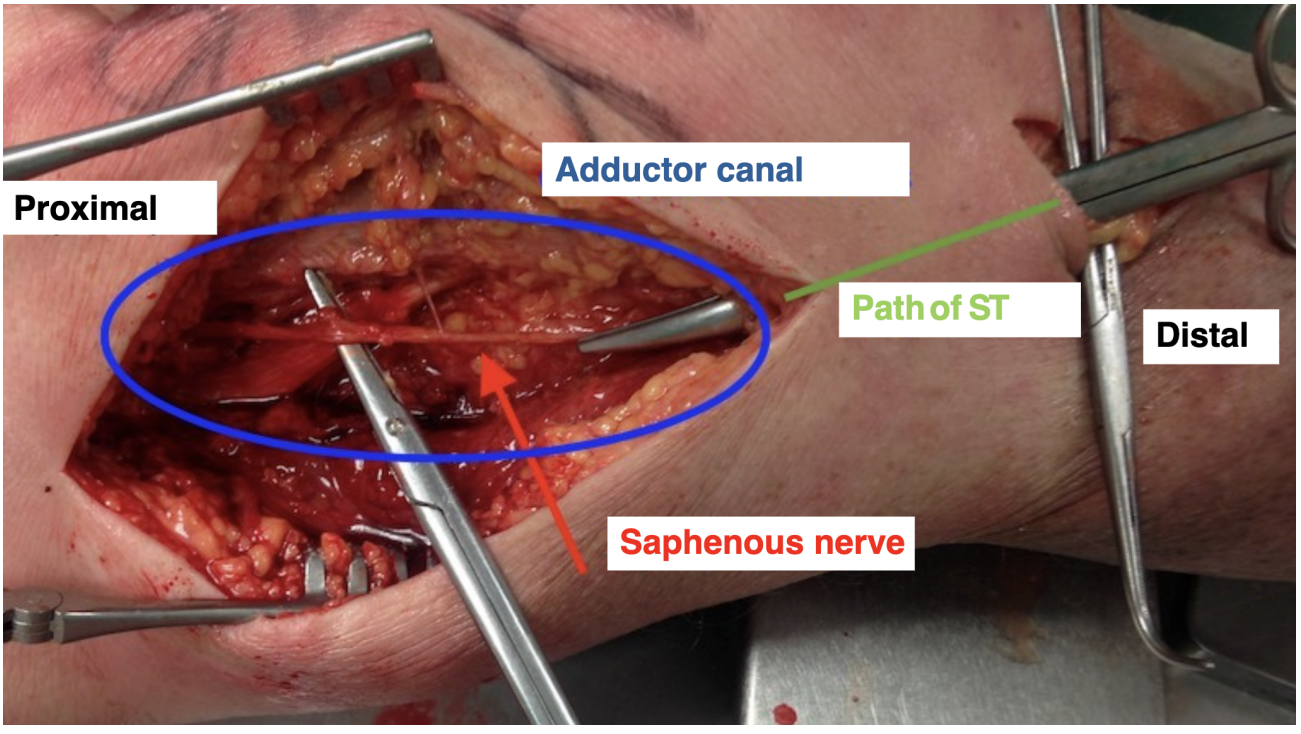

Figure 5: Infiltration along the path of the Semitendinosus Tendon (ST) . The red arrow indicates the adductor canal, the green arrow indicates the path of the Semitendinosus Tendon (ST), the blue oval shape indicates the adductor canal.

Hamstring harvesting Technique

Patient position

The knee is placed in the supine position in the standard arthroscopy position with a lateral post proximal to the knee at the level of the padded tourniquet, allowing full range of motion when desired.

Incision and Exposure:

The tibia tubercle is first identified through palpation and marked appropriately. The hamstring tendons are then palpated from the posterior thigh to the anteromedial aspect of the tibia at the insertion site. A 2 to 3 cm vertical anteromedial incision 1 cm medial and distal to the tibial tuberosity is performed and the subcutaneous skin is bluntly dissected to avoid injury of the IPBSN. A Farabeuf retractor can be utilized for exposure and to medially retract the IPBSN.

Identification of Tendons:

The sartorius fascia (SF) will be encountered as a thin layer overlying the hamstring tendon insertion. With the knee maintained at 90° flexion to tension the hamstring tendons, a "step-off" can be appreciated indicating the proximal border of the gracilis tendon. The SF is then incised transversely along the length of the tendon at the upper border of the gracilis, then the incision is extended longitudinally and distally in an "open-book" manner to evert the fascia, exposing the semitendinosus (ST) and gracilis (GT) tendons from proximal to distal.

Tendon Release:

Using two curved Kelly forceps, the tendons are retracted through the incision while maintaining their distal attachments to improve fixation and vascularity [45]. This is performed by using a mix of traction and counter-traction with the curved Kelly forceps. After dividing the common expansions, the individual expansions of the semitendinosus tendon (ST) and gracilis are cut with scissors under direct visual control until both tendons were individually freed (**Figure 7**).

Tendon Harvesting:

The semitendinosus and gracilis tendons are harvested with an open-ended tendon stripper using the surgeon's preferred method. If the stripper does not slide smoothly, any remaining expansions are freed to prevent tendon damage or premature truncation. The sartorial branch of the saphenous nerve (SBSN) can be observed between the gracilis and sartorius along the bone. Direct visualization of the SBSN can allow for safe placement of the tendon stripper and avoid iatrogenic nerve injury (**Figure 8**). Once the hamstrings are released from the musculotendinous attachments, the harvested tendons are wrapped in vancomycin-soaked swabs to reduce the risk of septic arthritis until graft preparation [46].

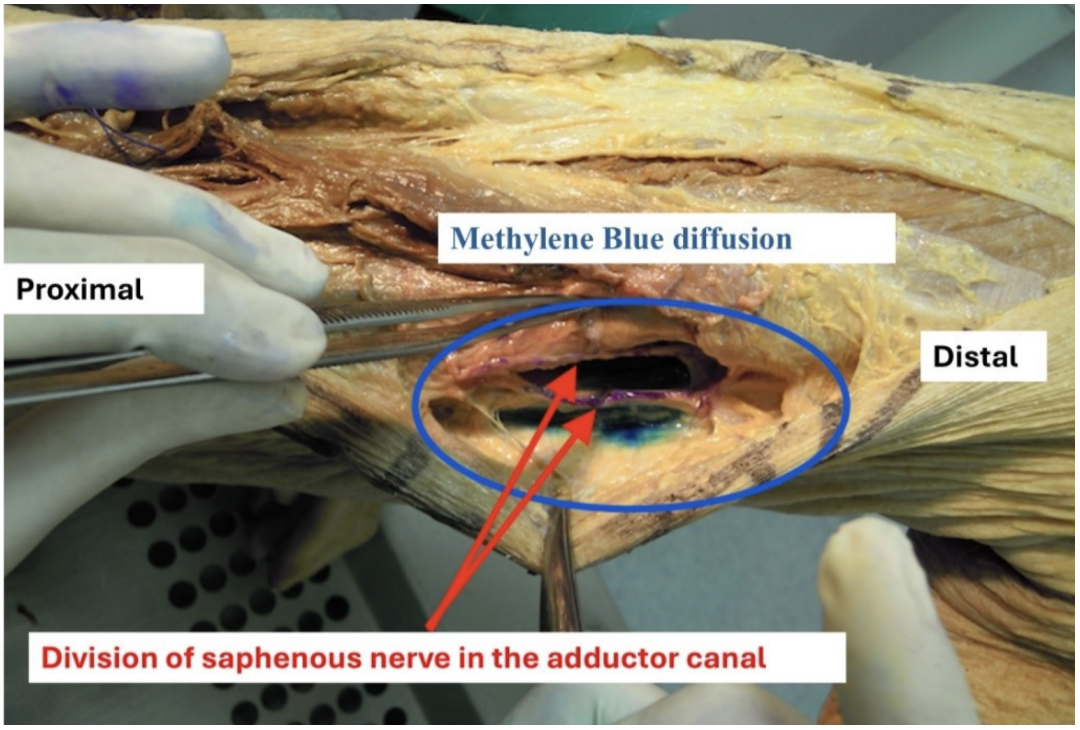

Figure 6: Evaluation of Methylene Blue diffusion in the adductor canal. The red arrows show the division of the saphenous nerve in the adductor canal. The blue oval shape show the diffusion of Methylene Blue in the canal.

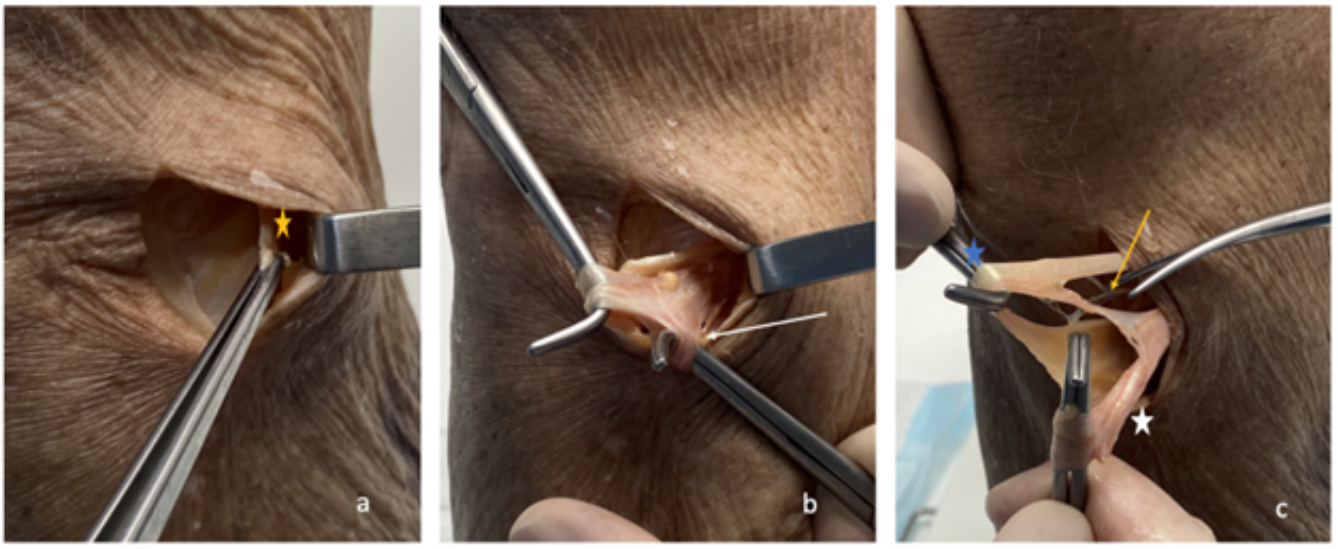

Figure 7: a) The SF (yellow star) incised horizontally at the upper border of the gracilis and extended laterally and distally in an "open-book" manner to evert the fascia. b) One of the curved Kelly forceps pull-outs the tendons meanwhile the other forceps, release them from the surrounding fascia and cut the individual expansions (white arrow) of the ST with scissors under direct visual control. c) common expansions (yellow arrow) between GT (white star) and gracilis (blue star) are dissected.

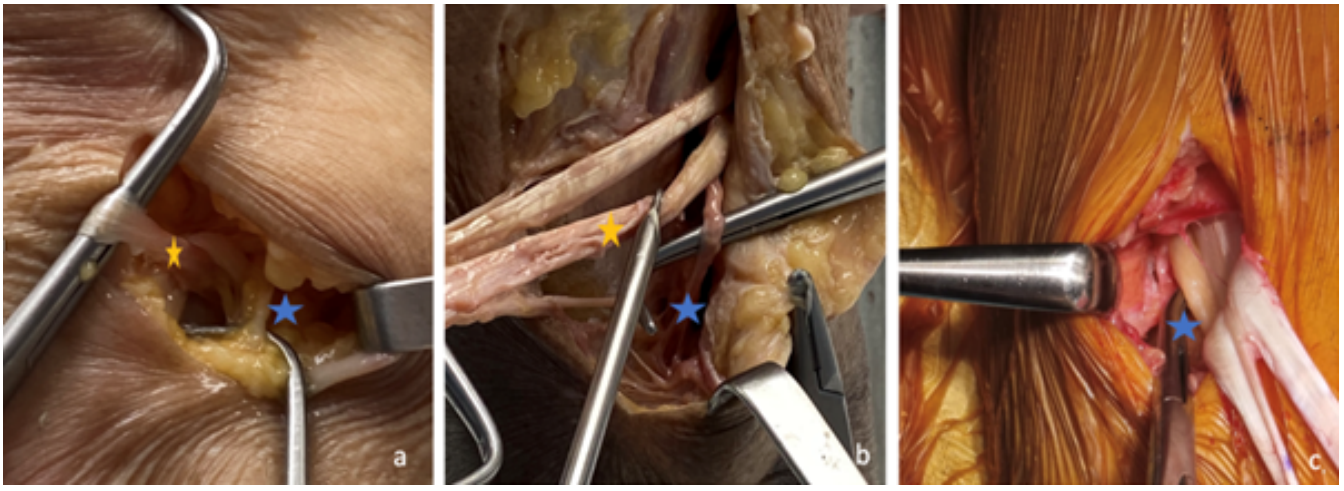

Figure 8: The sartorial branch of the saphenous nerve (SBSN) in relation with HT (blue star) a) SBSN is visualized under the ST (yellow star) b) Visualization of SBSN allows the surgeon to place the stripper correctly and avoid nerve injury under direct visualization c) Visualization of SBSN after ST and gracilis tendons were harvested.

Results

I. Anatomical findings

The saphenous nerve

The saphenous nerve was located on the medial aspect of the femoral artery within the adductor canal in all cases (18/18) (100%).

The infrapatellar branch of the saphenous (IPBSN)

The infrapatellar branch of the saphenous nerve was dissected in all cases (18/18) (100%) with a variant origin of 2/3 of the cases:

- High origin of the infrapatellar branch:

The saphenous nerve divided into its 2 main branches in the adductor canal in 12 of 18 cases (66.7%). The level of the saphenous nerve bifurcation was located on average 3 cm above the lower pole of the adductor canal (adductor hiatus) for all 12 cases (100%). In 10 out of 12 cases (83.3%), an anterior accessory branch of the infrapatellar ramus could be dissected (**Figure 9**).

- Low origin of the infrapatellar branch:

In 6 of 18 cases (33.3%), the nerve bifurcation was located caudal to the adductor canal (at the level of the distal femoral condyle). Two transverse branches of the infrapatellar ramus

were dissected in 4 of 6 cases (66.7%), anterior to the patellar tendon. The anatomy of the branches of the infrapatellar ramus were variable depending on the individual and laterality within the same subjects.

The sartorial branch (SBSN)

The sartorial ramus had a more constant, vertical course between the gracilis muscle and the sartorius muscle, running distally and behind the semitendinosus. The SBSN did not have any anatomical variation or accessory branches in the 18 dissected limbs.

The superficial accessory saphenous nerve

The superficial accessory saphenous nerve was dissected in 16 of 18 cases (88.9%) and gave rise to sensory branches leading to the patellar plexus in 12 of 16 cases (75%).

II. Results of the infiltration

Nine limbs were infiltrated with 20cc of methylene blue prior to dissection. The methylene blue infiltration technique was the same in all cases. In all cases (100%) there was dissemination to the saphenous nerve and its two main branches; whether the division was in the adductor canal or downstream at the adductor hiatus. The upper limit of diffusion was located at an average of 17 cm from the medial tibial condyle, at the level of the fascia between the vastus medialis and the adductor longus muscle (proximal part of the adductor canal). The femoral vascular bundle, the saphenous nerve and the medial aspect of the vastus medialis were in all cases stained with methylene blue.

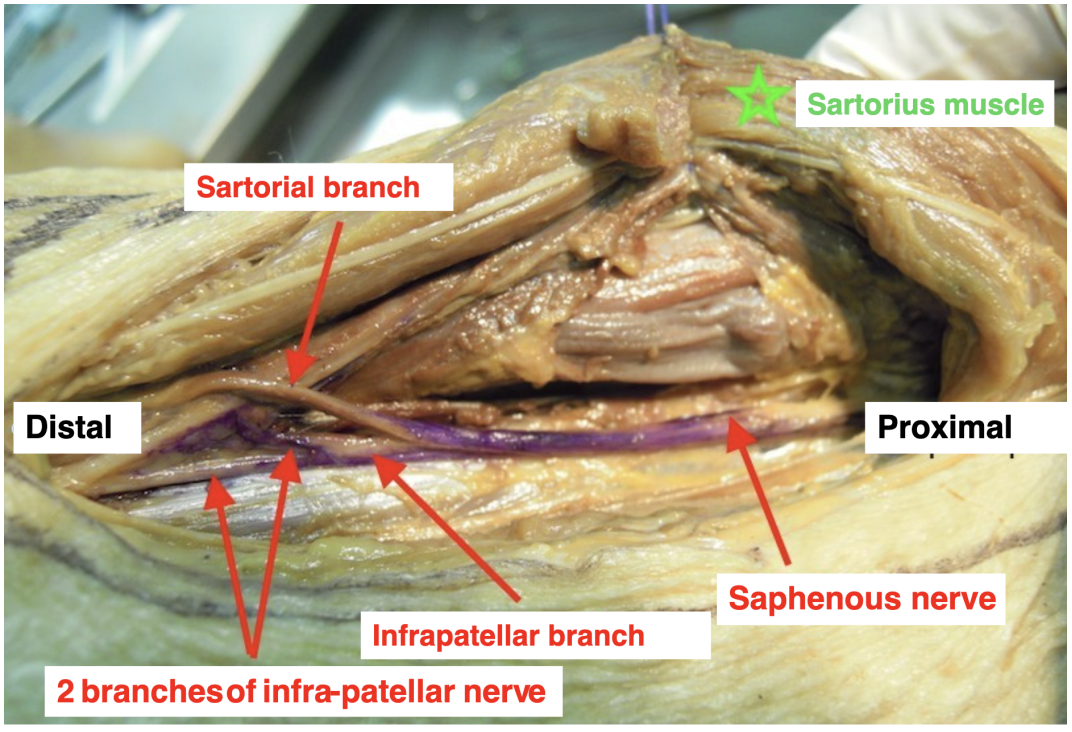

Figure 9: Presence of 2 branches of the infra patellar nerve in the adductor canal

Discussion

The saphenous nerve and its branches can be at risk during HT harvesting during ACLR procedures. Additionally, due its course in the adductor canal and sensory distribution of the knee, it is an appropriate candidate of LIA in decreasing post operative pain. This study was able to demonstrate direct visualization of the SBSN branches which are in close proximity to HT harvesting and can be at risk for iatrogenic injury. This study also demonstrates there is 100% infiltration of the saphenous nerve and its branches into the adductor canal after injecting methylene blue at the HT harvest site. Lastly, this study also highlighted the anatomical description of the saphenous nerve and its main branches (infrapatellar and sartorial branch) with the use of gross dissections which are consistent with the already published data in the literature [24][28][29][30][31][32][36].

Previous studies have demonstrated postoperative pain following an ACLR can be due to the surgical incision, the femoral and tibial tunnels, and the harvested graft site [47]. Although the femoral nerve block (FNB) provides adequate pain control due to the skin incision, the tunnels, and bone-patellar tendon-bone (BPTB) grafts [48], its role in managing pain from hamstring graft sites is limited [49]. Firstly, due to this limitation in HT harvesting, the first objective of this study was to provide detailed anatomic description of the

saphenous nerve through surgical dissection near the hamstring insertion site and to describe a reproducible technique for HT harvesting to decrease the risk of perioperative injury to the saphenous branches. Injury to the IPBSN and SBSN represents one of the most common complications of HS tendon harvest and subsequently post-operative pain.

The IPBSN splits from the saphenous nerve in a highly variable manner. It pierces the sartorius muscle, after which it runs a superficial course and generally forms two branches [30][32]. Both branches cross the patellar tendon transversely to form the infrapatellar plexus. The origin of the infrapatellar branches varies greatly between individuals and even between limbs within the same individual. This anatomical dissection revealed the main two branches of the IPBSN in 77.8% of the cases. Due to its subcutaneous position and horizontal course along the medial knee, the IPBSN is at risk of damage during skin incision, HS tendon harvest and tibial drilling during ACLR and its injury results in numbness on the anterior aspect of the knee and the proximal lateral part of the lower leg [28][30][32][34][35]. Due to this, the location of optimal skin incision has been controversial. It has been suggested that vertical skin incision should be avoided due to higher level of iatrogenic nerve injury [41]. Babu et al. suggested that a vertical incision is sufficient to expose the pes anserinus and to harvest HS tendons while minimizing damage to the IPBSN due to its distribution in the fatty layer [58]. In the author's technique, with gentle dissection and protection using a Farabeuf retractor, as described above, the procedure can be performed safely. Moreover, a vertical incision near the tibial tuberosity, as described, could also be reused in case of a revision ACLR requiring BPTB graft.

The sartorial terminal branch travels vertically toward the medial knee behind the sartorius, pierces the fascia between the sartorius and gracilis tendons, and travels distally. Sanders et al. [41] reported isolated sartorial terminal branch injuries at a rate of 23%. Iatrogenic damage to the sartorial terminal branch is thought to be related to the passage of the stripper during the gracilis tendon harvest. In the described technique above, the SBSN was observed in all the cases between the gracilis and ST after expansions were removed, allowing the surgeon to place the stripper correctly and avoid nerve injury under direct visualization.

Secondly, due to questionable FNB [22][49][50][51][52] efficacity in ACLR, an adductor canal block (ACB) can be also performed due to the more distal location of the nerve block allowing greater preservation of motor fibers that innervate the quadriceps muscle, and thus theoretically preserving more muscle strength [19][50]. However, an alternative option, local infiltration analgesia (LIA) through direct infiltration of local anesthetics to the donor site of the harvested hamstring tendons is a reliable alternative of pain management after ACLR as it avoids the potential risks of peripheral nerve block injection [37][53][54][55]. Stebler et al. [56] performed a randomized triple-blinded study and found no difference between ACB and LIA regarding the pain control and the functional outcomes. Sonnery-Cottet et al. [37] described in his prospective case-control study that intra-articular and hamstring donor site injections of local anesthetics do not differ significantly regarding the efficacy of postoperative pain relief or the use of rescue opiate analgesic therapy. Conversely, Buschnell et al. [53] found that an injection of the hamstring donor site with local anesthetic through an arthroscopic shaver sleeve showed a statistically significant improvement in postoperative pain levels in patients undergoing autogenous hamstring ACL reconstruction.

The second main objective was to analyze the diffusion of methylene blue infiltration through the harvesting site of the hamstring tendons into the adductor canal to better assess diffusion ability intraoperatively with local anesthetic. This technique is safe and reproducible without any described complication. Through the diffusion of the local anesthetic into the adductor canal branches of the saphenous nerve as well as the sensory branches of the vastus medialis is able to be blocked. This procedure avoids the intra-articular injection of a local anesthetic, which has been implicated in chondrotoxicity [53][57]. In all cases, the methylene blue spread to the proximal part of the adductor canal, ensuring different branches of the saphenous nerve were infiltrated. These results corroborate the already proven effectiveness of infiltration of the sampling site with local anesthetics by demonstrating the diffusion of the liquid in contact with the saphenous nerve [20][37][53].

Finally, this present study showed, in accordance with previous studies [30][32][59][60], that the anatomical topography of the IPBSN is highly variable. To the authors knowledge, it is the first to examine the diffusion of injected contrast medium by a 16 cm canula from the distal insertion of the gracilis and the semitendinosus under the sartorius fascia.

The study has several limitations. First, the sample size of the cadavers is limited. Additionally, there is a potential difference due to the use of methylene blue, which is water-soluble and may diffuse differently compared to the local anesthetics typically used. However, this effect is minimized by dissecting the limb after infiltration to avoid creating areas of detachment between the anatomical planes, as early dissection can alter diffusion patterns. Moreover, the use of non-fresh, formalin-preserved cadavers may affect tissue consistency and consequently the diffusion of the dye. Lastly, formalin preservation complicates the dissection of small-

diameter sensory branches, as it causes the fatty tissue to adhere to the nerves.

Conclusion

The great anatomical variability and the association of several possible origins for the main branches of the saphenous nerve at the level of the adductor canal probably explain the variable rate of effectiveness of the saphenous nerve block techniques found in the literature. Direct visualization of the SBSN branches, close to the HT expansions, must be recognized and appreciated to limit iatrogenic injury. Also, infiltration of the adductor canal via the hamstring donor site during autologous HT harvesting leads to diffusion to the saphenous nerve and its main branches which can be utilized intraoperatively with local anesthetic for reliable local analgesia.

Statements and Declarations

B.S.-C. received support and royalties from Arthrex.

Open access statement

This is an open-access article distributed under the terms of the Creative Commons Attribution Non-Commercial (**CC BY-NC 4.0,** see https://creativecommons.org/licenses/by-nc/4.0/) licence, which permits the sharing and adapting work, as long as it is for non-commercial purposes and proper credit is given to the original creator.

References

1. Desai VS, Anderson GR, Wu IT, Levy BA, Dahm DL, Camp CL, et al. Anterior Cruciate Ligament Reconstruction With Hamstring Autograft: A Matched Cohort Comparison of the All-Inside and Complete Tibial Tunnel Techniques. Orthop J Sports Med. 2019 Jan;7(1):2325967118820297. DOI: 10.1177/2325967118820297
2. Mall NA, Chalmers PN, Moric M, Tanaka MJ, Cole BJ, Bach BR, et al. Incidence and trends of anterior cruciate ligament reconstruction in the United States. Am J Sports Med. 2014 Oct;42(10):2363–70. DOI: 10.1177/0363546514542796
3. Prodromos CC, Han Y, Rogowski J, Joyce B, Shi K. A meta-analysis of the incidence of anterior cruciate ligament tears as a function of gender, sport, and a knee injury-reduction regimen. Arthroscopy. 2007 Dec;23(12):1320-1325.e6. DOI: 10.1016/j.arthro.2007.07.003
4. Sanders TL, Maradit Kremers H, Bryan AJ, Larson DR, Dahm DL, Levy BA, et al. Incidence of Anterior Cruciate Ligament Tears and Reconstruction: A 21-Year Population-Based Study. Am J Sports Med. 2016 Jun;44(6):1502–7. DOI: 10.1177/0363546516629944
5. Spindler KP, Wright RW. Clinical practice. Anterior cruciate ligament tear. N Engl J Med. 2008 Nov 13;359(20):2135–42. DOI: 10.1056/NEJMcp0804745
6. Delay BS, Smolinski RJ, Wind WM, Bowman DS. Current practices and opinions in ACL reconstruction and rehabilitation: results of a survey of the American Orthopaedic Society for Sports Medicine. Am J Knee Surg. 2001;14(2):85–91.
7. Mascarenhas R, Tranovich MJ, Kropf EJ, Fu FH, Harner CD. Bone-patellar tendon-bone autograft versus hamstring autograft anterior cruciate ligament reconstruction in the young athlete: a retrospective matched analysis with 2-10 year follow-up. Knee Surg Sports Traumatol Arthrosc. 2012 Aug;20(8):1520–7. DOI: 10.1007/s00167-011-1735-2
8. Webster KE, Feller JA, Hartnett N, Leigh WB, Richmond AK. Comparison of Patellar Tendon and Hamstring Tendon Anterior Cruciate Ligament Reconstruction: A 15-Year Follow-up of a Randomized Controlled Trial. Am J Sports Med. 2016 Jan;44(1):83–90. DOI: 10.1177/0363546515611886
9. Baverel L, Cucurulo T, Lutz C, Colombet null, Cournapeau J, Dalmay F, et al. Anesthesia and analgesia methods for outpatient anterior cruciate ligament reconstruction. Orthop Traumatol Surg Res. 2016 Dec;102(8S):S251–5. DOI: 10.1016/j.otsr.2016.08.007
10. Lu Y, Lavoie-Gagne O, Khazi Z, Patel BH, Mascarenhas R, Forsythe B. Inpatient admission following anterior cruciate ligament reconstruction is associated with higher postoperative complications. Knee Surg Sports Traumatol Arthrosc. 2020 Aug;28(8):2486–93. DOI: 10.1007/s00167-020-06094-2
11. Gregorian RS, Gasik A, Kwong WJ, Voeller S, Kavanagh S. Importance of side effects in opioid treatment: a trade-off analysis with patients and physicians. J Pain. 2010 Nov;11(11):1095–108. DOI: 10.1016/j.jpain.2010.02.007
12. Moutzouros V, Jildeh TR, Tramer JS, Meta F, Kuhlmann N, Cross A, et al. Can We Eliminate Opioids After Anterior Cruciate Ligament Reconstruction? A Prospective, Randomized Controlled Trial. Am J Sports Med. 2021 Dec;49(14):3794–801. DOI: 10.1177/03635465211045394
13. Secrist ES, Freedman KB, Ciccotti MG, Mazur DW, Hammoud S. Pain Management After Outpatient Anterior Cruciate Ligament Reconstruction: A Systematic Review of Randomized Controlled Trials. Am J Sports Med. 2016 Sep;44(9):2435–47. DOI: 10.1177/0363546515617737
14. Yung EM, Brull R, Albrecht E, Joshi GP, Abdallah FW. Evidence Basis for Regional Anesthesia in Ambulatory Anterior Cruciate Ligament Reconstruction: Part III: Local Instillation Analgesia-A Systematic Review and Meta-analysis. Anesth Analg. 2019 Mar;128(3):426–37. DOI: 10.1213/ANE.0000000000002599
15. Andrés-Cano P, Godino M, Vides M, Guerado E. Postoperative complications of anterior cruciate ligament reconstruction after ambulatory surgery. Rev Esp Cir Ortop Traumatol. 2015;59(3):157–64. DOI: 10.1016/j.recot.2014.09.001
16. Lentz TA, Tillman SM, Indelicato PA, Moser MW, George SZ, Chmielewski TL. Factors associated with function after anterior cruciate ligament reconstruction. Sports Health. 2009 Jan;1(1):47–53. DOI: 10.1177/1941738108326700
17. Vorobeichik L, Brull R, Joshi GP, Abdallah FW. Evidence Basis for Regional Anesthesia in Ambulatory Anterior Cruciate Ligament Reconstruction: Part I-Femoral Nerve Block. Anesth Analg. 2019 Jan;128(1):58–65. DOI: 10.1213/ANE.0000000000002854

18. Bianchi S, Martinoli C, Demondion X. Ultrasound of the nerves of the knee region: Technique of examination and normal US appearance. J Ultrasound. 2007 Jun;10(2):68–75. DOI: 10.1016/j.jus.2007.04.004

19. Espelund M, Grevstad U, Jaeger P, Hölmich P, Kjeldsen L, Mathiesen O, et al. Adductor canal blockade for moderate to severe pain after arthroscopic knee surgery: a randomized controlled trial. Acta Anaesthesiol Scand. 2014 Nov;58(10):1220–7. DOI: 10.1111/aas.12407

20. Faunø P, Lund B, Christiansen SE, Gjøderum O, Lind M. Analgesic effect of hamstring block after anterior cruciate ligament reconstruction compared with placebo: a prospective randomized trial. Arthroscopy. 2015 Jan;31(1):63–8. DOI: 10.1016/j.arthro.2014.07.024

21. Franz W, Baumann A. Minimally invasive semitendinosus tendon harvesting from the popliteal fossa versus conventional hamstring tendon harvesting for ACL reconstruction: A prospective, randomised controlled trial in 100 patients. Knee. 2016 Jan;23(1):106–10. DOI: 10.1016/j.knee.2015.09.001

22. Luo TD, Ashraf A, Dahm DL, Stuart MJ, McIntosh AL. Femoral nerve block is associated with persistent strength deficits at 6 months after anterior cruciate ligament reconstruction in pediatric and adolescent patients. Am J Sports Med. 2015 Feb;43(2):331–6. DOI: 10.1177/0363546514559823

23. Sehmbi H, Brull R, Shah UJ, El-Boghdadly K, Nguyen D, Joshi GP, et al. Evidence Basis for Regional Anesthesia in Ambulatory Arthroscopic Knee Surgery and Anterior Cruciate Ligament Reconstruction: Part II: Adductor Canal Nerve Block-A Systematic Review and Meta-analysis. Anesth Analg. 2019 Feb;128(2):223–38. DOI: 10.1213/ANE.0000000000002570

24. Andersen HL, Andersen SL, Tranum-Jensen J. The spread of injectate during saphenous nerve block at the adductor canal: a cadaver study. Acta Anaesthesiol Scand. 2015 Feb;59(2):238–45. DOI: 10.1111/aas.12451

25. Hanson NA, Derby RE, Auyong DB, Salinas FV, Delucca C, Nagy R, et al. Ultrasound-guided adductor canal block for arthroscopic medial meniscectomy: a randomized, double-blind trial. Can J Anaesth. 2013 Sep;60(9):874–80. DOI: 10.1007/s12630-013-9992-9

26. Horn JL, Pitsch T, Salinas F, Benninger B. Anatomic basis to the ultrasound-guided approach for saphenous nerve blockade. Reg Anesth Pain Med. 2009;34(5):486–9. DOI: 10.1097/AAP.0b013e3181ae11af

27. Walshaw T, Karuppiah SV, Stewart I. The course and distribution of the infra patellar nerve in relation to ACL reconstruction. Knee. 2015 Oct;22(5):384–8. DOI: 10.1016/j.knee.2014.11.003

28. Arthornthurasook A, Gaew-Im K. Study of the infrapatellar nerve. Am J Sports Med. 1988;16(1):57–9. DOI: 10.1177/036354658801600110

29. Dunaway DJ, Steensen RN, Wiand W, Dopirak RM. The sartorial branch of the saphenous nerve: its anatomy at the joint line of the knee. Arthroscopy. 2005 May;21(5):547–51. DOI: 10.1016/j.arthro.2005.02.019

30. Ebraheim NA, Mekhail AO. The infrapatellar branch of the saphenous nerve: an anatomic study. J Orthop Trauma. 1997 Apr;11(3):195–9. DOI: 10.1097/00005131-199704000-00010

31. Hunter LY, Louis DS, Ricciardi JR, O'Connor GA. The saphenous nerve: its course and importance in medial arthrotomy. Am J Sports Med. 1979;7(4):227–30. DOI: 10.1177/036354657900700403

32. Kerver ALA, Leliveld MS, den Hartog D, Verhofstad MHJ, Kleinrensink GJ. The surgical anatomy of the infrapatellar branch of the saphenous nerve in relation to incisions for anteromedial knee surgery. J Bone Joint Surg Am. 2013 Dec 4;95(23):2119–25. DOI: 10.2106/JBJS.L.01297

33. McGinnis MD, Gonzalez R, Nyland J, Caborn DNM. The posteromedial knee arthroscopy portal: a cadaveric study defining a safety zone for portal placement. Arthroscopy. 2011 Aug;27(8):1090–5. DOI: 10.1016/j.arthro.2011.02.031

34. Mochida H, Kikuchi S. Injury to infrapatellar branch of saphenous nerve in arthroscopic knee surgery. Clin Orthop Relat Res. 1995 Nov;(320):88–94.

35. Papastergiou SG, Voulgaropoulos H, Mikalef P, Ziogas E, Pappis G, Giannakopoulos I. Injuries to the infrapatellar branch(es) of the saphenous nerve in anterior cruciate ligament reconstruction with four-strand hamstring tendon autograft: vertical versus horizontal incision for harvest. Knee Surg Sports Traumatol Arthrosc. 2006 Aug;14(8):789–93. DOI: 10.1007/s00167-005-0008-3

36. Wijdicks CA, Westerhaus BD, Brand EJ, Johansen S, Engebretsen L, LaPrade RF. Sartorial branch of the saphenous nerve in relation to a medial knee ligament repair or reconstruction. Knee Surg Sports Traumatol Arthrosc. 2010 Aug;18(8):1105–9. DOI: 10.1007/s00167-009-0934-6

37. Sonnery-Cottet B, Saithna A, Azeem A, Choudja E, Pic JB, Cabaton J, et al. Analgesia after ACL reconstruction: Hamstring donor-site injection versus intra-articular local anaesthetic injection. Orthop Traumatol Surg Res. 2017 Apr;103(2):235–8. DOI: 10.1016/j.otsr.2016.11.011

38. Albishi W, Baltow B, Albusayes N, Sayed AA, Alrabai HM. Hamstring autograft utilization in reconstructing anterior cruciate ligament: Review of harvesting techniques, graft preparation, and different fixation methods. World J Orthop. 2022 Oct 18;13(10):876–90. DOI: 10.5312/wjo.v13.i10.876

39. Hardy A, Casabianca L, Andrieu K, Baverel L, Noailles T, Junior French Arthroscopy Society. Complications following harvesting of patellar tendon or hamstring tendon grafts for anterior cruciate ligament reconstruction: Systematic review of literature. Orthop Traumatol Surg Res. 2017 Dec;103(8S):S245–8. DOI: 10.1016/j.otsr.2017.09.002

40. Olivos-Meza A, Suarez-Ahedo C, Jiménez-Aroche CA, Pantanali N, Valdez-Chávez MV, Pérez-Jiménez FJ, et al. Anatomic Considerations in Hamstring Tendon Harvesting for Ligament Reconstruction. Arthrosc Tech. 2020 Jan;9(1):e191–8. DOI: 10.1016/j.eats.2019.09.021

41. Sanders B, Rolf R, McClelland W, Xerogeanes J. Prevalence of saphenous nerve injury after autogenous hamstring harvest: an anatomic and clinical study of sartorial branch injury. Arthroscopy. 2007 Sep;23(9):956–63. DOI: 10.1016/j.arthro.2007.03.099

42. Gousopoulos L, Grob C, Ahrens P, Levy Y, Vieira TD, Sonnery-Cottet B. How to Avoid Iatrogenic Saphenous Nerve Injury During Outside-In or Inside-Out Medial Meniscus Sutures. Arthrosc Tech. 2022 Feb;11(2):e127–32. DOI: 10.1016/j.eats.2021.09.012

43. Peltier E, Berdugo L, Cucurulo T. Étude anatomique cadavérique du nerf saphène et intérêt dans l'analgésie de la ligamentoplastie du ligament croisé antérieur aux tendons ischiojambiers. Revue de Chirurgie Orthopédique et Traumatologique. 2016 Dec;Volume 102, Issue 8, Supplement:S299.

44. Sonnery-Cottet B, Daggett M, Helito CP, Fayard JM, Thaunat M. Combined Anterior Cruciate Ligament and Anterolateral Ligament Reconstruction. Arthrosc Tech. 2016 Dec;5(6):e1253–9. DOI: 10.1016/j.eats.2016.08.003

45. Zaffagnini S, Golanò P, Farinas O, Depasquale V, Strocchi R, Cortecchia S, et al. Vascularity and neuroreceptors of the pes anserinus: anatomic study. Clin Anat. 2003 Jan;16(1):19–24. DOI: 10.1002/ca.10073

46. Carrozzo A, Saithna A, Ferreira A, Guy S, Chadli L, Monaco E, et al. Presoaking ACL Grafts in Vancomycin Decreases the Frequency of Postoperative Septic Arthritis: A Cohort Study of 29,659 Patients, Systematic Review, and Meta-analysis From the SANTI Study Group. Orthop J Sports Med. 2022 Feb;10(2):23259671211073928. DOI: 10.1177/23259671211073928

47. Feller JA, Webster KE, Gavin B. Early post-operative morbidity following anterior cruciate ligament reconstruction: patellar tendon versus hamstring graft. Knee Surg Sports Traumatol Arthrosc. 2001 Sep;9(5):260–6. DOI: 10.1007/s001670100216

48. Frost S, Grossfeld S, Kirkley A, Litchfield B, Fowler P, Amendola A. The efficacy of femoral nerve block in pain reduction for outpatient hamstring anterior cruciate ligament reconstruction: a double-blind, prospective, randomized trial. Arthroscopy. 2000 Apr;16(3):243–8. DOI: 10.1016/s0749-8063(00)90047-1

49. Mall NA, Wright RW. Femoral nerve block use in anterior cruciate ligament reconstruction surgery. Arthroscopy. 2010 Mar;26(3):404–16. DOI: 10.1016/j.arthro.2009.08.014

50. Abdallah FW, Brull R, Joshi GP, Society for Ambulatory Anesthesia (SAMBA). Pain Management for Ambulatory Arthroscopic Anterior Cruciate Ligament Reconstruction: Evidence-Based Recommendations From the Society for Ambulatory Anesthesia. Anesth Analg. 2019 Apr;128(4):631–40. DOI: 10.1213/ANE.0000000000003976

51. Everhart JS, Hughes L, Abouljoud MM, Swank K, Lewis C, Flanigan DC. Femoral nerve block at time of ACL reconstruction causes lasting quadriceps strength deficits and may increase short-term risk of re-injury. Knee Surg Sports Traumatol Arthrosc. 2020 Jun;28(6):1894–900. DOI: 10.1007/s00167-019-05628-7

52. Swank KR, DiBartola AC, Everhart JS, Kaeding CC, Magnussen RA, Flanigan DC. The Effect of Femoral Nerve Block on Quadriceps Strength in Anterior Cruciate Ligament Reconstruction: A Systematic Review. Arthroscopy. 2017 May;33(5):1082-1091.e1. DOI: 10.1016/j.arthro.2017.01.034

53. Bushnell BD, Sakryd G, Noonan TJ. Hamstring donor-site block: evaluation of pain control after anterior cruciate ligament reconstruction. Arthroscopy. 2010 Jul;26(7):894–900. DOI: 10.1016/j.arthro.2009.11.022

54. Johnson RL, Kopp SL, Hebl JR, Erwin PJ, Mantilla CB. Falls and major orthopaedic surgery with peripheral nerve blockade: a systematic review and meta-analysis. Br J Anaesth. 2013 Apr;110(4):518–28. DOI: 10.1093/bja/aet013

55. Kristensen PK, Pfeiffer-Jensen M, Storm JO, Thillemann TM. Local infiltration analgesia is comparable to femoral nerve block after anterior cruciate ligament reconstruction with hamstring tendon graft: a randomised controlled trial. Knee Surg Sports Traumatol Arthrosc. 2014 Feb;22(2):317–23. DOI: 10.1007/s00167-013-2399-x

56. Stebler K, Martin R, Kirkham KR, Lambert J, De Sede A, Albrecht E. Adductor canal block versus local infiltration analgesia for postoperative pain after anterior cruciate ligament reconstruction: a single centre randomised controlled triple-blinded trial. Br J Anaesth. 2019 Aug;123(2):e343–9. DOI: 10.1016/j.bja.2019.04.053

57. Danieli MV, Cavazzani Neto A, Herrera PA. Intra-articular bupivacaine or bupivacaine and morphine after ACL reconstruction. Acta Ortop Bras. 2012;20(5):258–61. DOI: 10.1590/S1413-78522012000500002

58. Babu S, Gupte C, Gajjar S, Morris H. The 'sentinel' vessel: an anatomical landmark to identify the pes anserinus during hamstrings harvest for ACL reconstruction. Eur J Orthop Surg Traumatol. 2019 Jul;29(5):1115–8. DOI: 10.1007/s00590-019-02408-4

59. Anagnostopoulou S, Anagnostis G, Saranteas T, Mavrogenis AF, Paraskeuopoulos T. Saphenous and Infrapatellar Nerves at the Adductor Canal: Anatomy and Implications in Regional Anesthesia. Orthopedics. 2016;39(2):e259-262. DOI: 10.3928/01477447-20160129-03

60. Kalthur SG, Sumalatha S, Nair N, Pandey AK, Sequeria S, Shobha L. Anatomic study of infrapatellar branch of saphenous nerve in male cadavers. Ir J Med Sci. 2015 Mar;184(1):201–6. DOI: 10.1007/s11845-014-1087-2