Open Latarjet for Acute Anterior Dislocation with Severe Anterior Glenoid Rim Fractures Provides Stable but Arthritic Shoulder at Long-term Follow-up

Esteban Andres Lobos Centeno [1], Dominique Saragaglia [2], Vincent Martinel [3], Johannes Barth [1 2] (*)

(*) corresponding author: j@drbarth.fr
1. Department of Orthopedic Surgery, Clinique des Cèdres, Grenoble, France
2. Service de Chirurgie Orthopédique et de Traumatologie du Sport C.H.U. de Grenoble - Hôpital Sud, Grenoble, France
3. Orthopédique Group Ormeau Pyrénées, Polyclinique de l'Ormeau ELSAN, Tarbes, France

Background: Large anterior glenoid rim fractures, known as Ideberg IIa, particularly those with persistent static subluxation despite appropriate immobilization, are best treated by reduction and internal fixation, utilizing either open or combined arthroscopic techniques.

Purpose: This study evaluated functional and radiological results of acute shoulder dislocations, associated with a large bone avulsion of the antero-inferior glenoid rim, treated with a modified Latarjet procedure.

Materials and Methods: From January 1991 to December 2000, 12 patients were admitted with an acute anterior dislocation associated with an anterior glenoid rim fracture greater than one-third of its glenoid surface. The sample was composed of 7 males and 5 females. Ten of them underwent an Open Reduction and Internal Fixation, using the modified Latarjet procedure. A standard deltopectoral approach was used, followed by coracotomy and reduction of the glenoid fragment, fixed with a 3.5 mm cortical screw. The coracoid graft was then placed in front of the fragment and secured with a malleolar screw, creating a "bone block sandwich". The subscapularis tendon was reattached to its humeral stump. The Mean age was of 57 years old (range, 25-82). A direct trauma was involved in 67 % of the cases. The patients were assessed according to Constant score and had X-rays evaluation (Samilson criteria).

Results: 9 of the 10 operated patients could be followed up. The Mean follow-up was 6 years (range, 3-11 years). None had shoulder instability. The mean Constant score was 82.2/100 (with a difference of 16.1 points compared to the other side). The mean weighted Constant score was 88.6/100. Two patients showed severe osteoarthritis images on the X-ray findings (stage 4). We also observed three stages 2, one stage 1, and two normal X-rays. In three cases, the coracoid bone block was slightly lateralized.

Conclusion: The modified Latarjet procedure provided stable shoulder outcomes in patients with large glenoid rim fractures (>20%). However, glenohumeral osteoarthritis was observed in 63% of cases at mid- to long-term follow-up, regardless of age.

What this study adds: This study provides surgical details on performing an open reduction and internal fixation for a large anterior glenoid rim fracture (Ideberg IIa) with the combined coracotomy to ease the approach, subsequently associated with the Latarjet technique to increase stability. Stability is achieved in all cases; however, concerns about osteoarthritis in long-term follow-up are noted.

Potential impacts on research, practice, or policy: The quality of reduction and stability should not be the sole focus of our research; the long-term evaluation of osteoarthritis must be considered, regardless of whether nonoperative or surgical techniques are chosen for severe anterior glenoid rim fractures. Further research is necessary to understand the cause of this osteoarthritis, whether it is due to the trauma or the surgical technique.

Study Design: Retrospective study

Level of Evidence: Level 4

Keywords: Bony Bankart; Anterior glenoid rim fracture; Anterior shoulder instability; Latarjet; Post-instability osteoarthritis; Ideberg IIa.

https://doi.org/10.70885/hmsj.2025.05.003

Introduction

The glenohumeral joint is among the most flexible joints in the human body, which also makes it one of the most unstable [1]. The incidence has been reported to be as high as 23.9 per 100,000 person-years [2]. The most prevalent type of glenohumeral instability is anterior, responsible for over 90% of all shoulder dislocations [3]. A common injury associated with anterior shoulder dislocation is the Bankart lesion [4]. The Bankart lesion is classically defined as detachment of the anteroinferior labrum. Still, this soft-tissue injury can be combined with a fracture of the anterior glenoid rim, described as a bony Bankart lesion (BBL) [5][6][7].

Glenoid defects greater than 20% have been associated with glenohumeral instability, resulting in recurrent dislocations, persistent pain, mal-union, and early onset osteoarthritis [8] [9]. Among these, Ideberg type IIA fractures—characterized by large avulsion fragments overhanging the scapular neck**,** particularly those with persistent static subluxation despite appropriate immobilization**—**often require surgical fixation rather than conservative treatment or soft-tissue repair alone [10].

Surgical options for treating large anterior glenoid defects include open or arthroscopic internal fixation techniques, as well as bone augmentation procedures. One of the most widely adopted techniques in such cases is the Latarjet procedure, which involves transferring the coracoid process to the anterior glenoid to restore stability through a triple mechanism: the bony increase of the glenoid arc, the sling effect of the conjoined tendon, and capsular tensioning. Over the years, various modifications of the original technique have been developed including the congruent-arc Latarjet, which involves rotating the coracoid to align its concave surface with the glenoid, and arthroscopic approaches that aim to reduce invasiveness while preserving outcomes [8] [10].

In our department, a derivative Latarjet procedure is used to treat this fracture. We chose this procedure for its easier approach to the joint with a proper view of the antero-inferior glenoid rim and its secure outcomes according to stability. The study aimed to evaluate this technique on stability, range of motions (ROM), and to determine the prevalence of gleno-humeral osteoarthritis.

Materials and Methods

From January 1991 to December 2000, 451 patients were admitted to our department with an acute anterior dislocation. Twelve patients (2.7%) had a fracture of the anterior glenoid rim with an Ideberg type IIA with >20% of its glenoid surface, involving 7 males and 5 females, 8 right shoulders and 4 left shoulders (**Figure 1A**). The mean age was 57 years old (range, 25-82).

A direct trauma, with a direct impact on the shoulder girdle, occurred in 8 cases (67%), while the other 4 cases (33%) fell on the palm of their hand. Half of the patients (6 patients) had a sport-related injury; 2 patients had a traffic injury, and 4 patients had a home-accident. No work-related injuries were registered. Only 10 patients underwent open-operative surgery, derived from the Latarjet procedure. The two other patients in the sample (aged 70 and 82 years) were treated conservatively, with a sling for 2 weeks, followed by an early rehabilitation protocol.

Surgical Technique

A deltopectoral approach was performed from the coracoid process distally for approximately 4–5 cm. A coracotomy was carried out to properly expose the glenoid; the conjoined tendon remained attached to the coracoid. The superior half of the subscapularis tendon was incised vertically, 1 cm medial to its humeral insertion, and extended horizontally toward the glenoid to create an L-shaped incision (**Figure 1B**). The capsulotomy was performed vertically [11].

The anterior glenoid rim fragment was identified, and both the capsule and labrum were excised to allow optimal exposure and reduction. The bony fragment was then anatomically reduced and stabilized using a single 3.5 mm cortical screw. The coracoid graft was prepared and oriented in a horizontal lying position with its inferior surface facing the glenoid. It was placed directly in front of the reduced fragment, and a malleolar screw was used to fix the coracoid, securing the construct in a “bone block sandwich” configuration.

Care was taken to avoid screw collision by planning the trajectories in advance. When a small fragment required fixation, one cortical screw was used first. The malleolar screw was then inserted superiorly and anteriorly, above the line of the first screw. In cases involving a larger fragment requiring two screws for fixation, the malleolar screw was positioned in between, avoiding interference with the fragment screws (**Figure 1C**).

Finally, the subscapularis tendon was reattached to its original humeral insertion using non-absorbable sutures, completing the repair [11].

Our goal was to assess the outcomes of our surgical technique, as performed for the ten patients of the study group.

At the time of follow-up, a clinical exam of the shoulder, completed with a Constant score, was performed. A weighted Constant score according to age and gender was also calculated.

Radiological exam (using AP, Lamy (Y), and Bernageau views) was conducted in order to evaluate osteoarthritis (according to Samilson criteria) [12] and the position of the coracoid bone block (**Figure 2**).

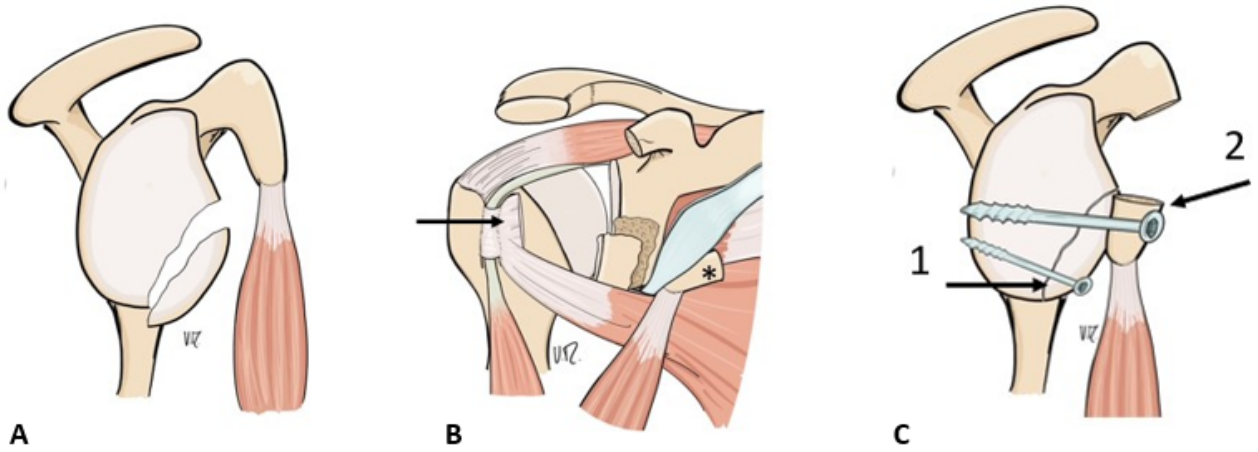

Figure 1A. Fracture glenoid rim > 20%. B. Glenoid fracture exposure. Vertical incision of the upper half of the subscapularis an L-shaped incision (arrow). Coracotomy (asterisk). C. Reduced bone fragment and fixed with a single cortical screw (arrow 1). The coracoid graft was positioned horizontally with its inferior surface facing the glenoid and fixed in front of the reduced fragment using a malleolar screw, creating a bone block sandwich configuration (arrow 2).

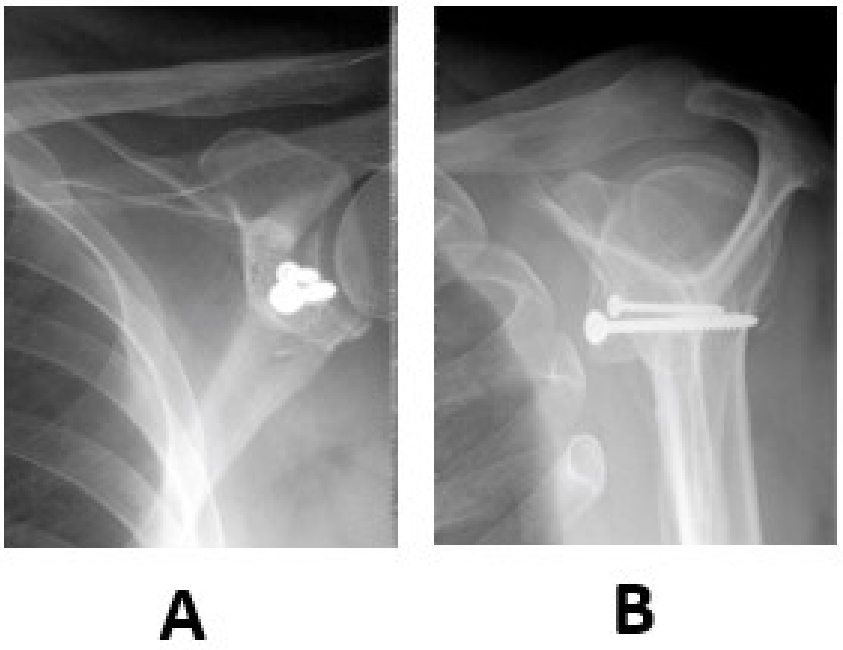

Figure 2. Postoperative radiograph. Front view (A). Lammy view (B).

Results

The mean follow up was 82 months (range, 36-132 months), it was performed by one single physician author (JB). Before the injury, their activity level was intensive in 3 cases, moderate in 4 cases and week in 2 cases. For seven patients, the injury occurred at the dominant side (77.8%).

Range of Motion

The mean active anterior elevation was 161°, showing a difference of 13° compared to the opposite side. The mean active abduction was 158°, with a 16° difference relative to the opposite side. The mean active external rotation with the arm at the side was 44°, showing a 12° difference from the opposite side. For active external rotation with the arm in 90° abduction, the mean was 60°, with a 23° difference compared to the opposite side. The mean active internal rotation, based on the Constant score, was 7.3/10, with a difference of 2/10 when compared to the opposite side (**Table 1**).

Table 1. Clinical Findings

	Involved side	Side to side difference
Active Forward elevation	161°	13°
Active External rotation (arm at the side)	44°	12°
Active Internal rotation	7.3/10	2
Constant Score	82.2/100	16.1
Weighted Constant Score adjusted to age and gender	88.6/100	

Table 2. Radiological Osteoarthritis Evaluation

Radiographic Parameter	n (%)	Age	Comments
Osteoarthritis Grade (Samilson's criteria)			
– Stage 0 (normal)	2 (25%)	49	No degenerative changes
		54	
– Stage 1 (mild)	1 (12.5%)	25	Slight joint space narrowing
– Stage 2 (moderate)	3 (37.5%)	48	Osteophyte formation + sclerosis
		55	
		57	
– Stage 4 (severe)	2 (25%)	82	Joint space obliteration and osteophytes
		64	
Coracoid Bone Block Position (Allain's criteria)			
– Anatomical/medial	6 (75%)		Optimal positioning
– Slight lateralization	2 (25%)		Associated with higher arthropathy rate

Functional Score

The mean Constant score was 82.2/100, with a difference of 16.1 points compared to the contralateral side. The mean weighted Constant score, adjusted for age and gender, was 88.6/100. Out of the patients evaluated, four reported being very satisfied and 2 were satisfied, yielding a total satisfaction rate (satisfied and very satisfied) of 66.7%. Three patients expressed mild satisfaction, and no patients reported being disappointed.

Out of the 10 patients who underwent surgery, one experienced a complication, specifically a superficial infection that required drainage. There were no cases of shoulder stiffness or neurological complications. Follow-up was achieved in 9 out of the 10 patients, representing a 90% follow-up rate. Postoperatively, none of the patients

experienced either chronic or acute instability. Union was achieved in all patients. There was no loss of reduction, non-union, or re-operations for instability.

X-Ray Findings

Eight patients consented to undergo radiographic evaluation. Osteoarthritis was assessed according to Samilson's criteria: two patients presented with severe osteoarthritis (stage 4), three with stage 2, one with stage 1, and two had normal X-rays (**Table 2**). The position of the coracoid bone block was evaluated following Allain's criteria [13], with two cases showing slight lateralization of the coracoid bone block.

Discussion

The main finding of this study is that after a mean follow-up period of 6.8 years, the open Latarjet procedure for acute anterior dislocation with severe anterior glenoid rim fractures provides a stable shoulder with a high satisfaction rate. However, signs of osteoarthritis were recorded in 63% of cases, the presence of osteoarthritis had only a minor impact on clinical outcome parameters. What distinguishes our approach from traditional Latarjet procedures is the surgical sequence: we first perform open reduction and internal fixation of the bony fragment, aiming to restore the native glenoid contour. The coracoid process is then positioned in front of the reconstructed rim and fixed with a malleolar screw, effectively buttressing the repair and enhancing anterior shoulder stability. We refer to this configuration as a "bone block sandwich," with the coracoid graft acting not as a primary filler of a bony void, but rather as a stabilizing overlay. This dual approach may optimize both anatomical and biomechanical restoration of the joint.

Gordins et al. reported that BBLs are more frequent in patients over 50 years old [14], in contrast to primary anterior shoulder dislocations, which typically affect younger patients (mean age 35 years) [2]. Age-related biomechanical changes, such as decreased capsular elasticity and reduced bone quality, may contribute to this difference [15][16]. For anterior glenoid rim fractures with fragments larger than 5 mm or involving more than 20% of the glenoid surface, surgical reduction and fixation is generally recommended [17].

Various fixation techniques have been developed over time. Sugaya introduced suture anchor fixation in 2005, followed by Tauber with cannulated titanium screws in 2008 [18][19]. In 2009, Millett described the bony Bankart bridge technique using two-point suture anchor fixation [17]. Arthroscopic bony Bankart repair has shown improved functional outcomes and high return-to-sport rates in cases with <25% glenoid bone loss, with an 11% recurrence rate [20], although concerns remain regarding subscapularis detachment and postoperative ROM recovery [21]. Several authors have highlighted the advantages of arthroscopy-assisted reduction and internal fixation (ARIF) over open techniques, citing less soft tissue dissection and fewer postoperative muscular complications [19][22]. Bonnevialle et al. found no significant clinical differences between open and arthroscopic approaches at 30-month follow-up, although the open group had higher postoperative complication rates (p=0.03), and no differences in glenohumeral arthritis (18% vs. 10%, p=0.65) [22]. Nevertheless, arthroscopic management is challenging in cases with multiple or small fragments or those extending into the scapular neck or body [23][24]. There's also a risk of "postage stamp" fractures at prior anchor sites, which can result in recurrent instability [25][26]. Moreover, the arthroscopic technique requires significant surgical experience, and in most of these fractures, an open approach is preferred to achieve an adequate reduction [8][27][28][29].

Open reduction and internal fixation (ORIF) is essential to restore anterior glenoid rim congruence and ensure stable fixation for early mobilization [30]. Scheibel et al. and Raiss et al. reported favorable clinical and radiologic outcomes for acute anterior glenoid rim fractures involving over 25% of the surface [17][31]. Giordano et al. described a safe approach using a vertical axillary incision, 2.0 mm screws, and labral repair, with minimal complications and residual instability [21]. The combination of ORIF with the Latarjet technique has demonstrated high patient satisfaction and no recurrences due to the "triple locking effect" (bone block, Bankart repair, and subscapularis sling effect) [32][33].

In our study, we observed a high rate of glenohumeral osteoarthritis (63%), including two cases of severe OA (stage 4) associated with lateralization of the bone graft. Malposition of the coracoid block has been linked to higher arthropathy rates (17%) compared to medial positioning 2–4 mm from the glenoid rim (8%) [34]. Boehm et al. reported a 50% rate of osteoarthritis at 10-year follow-up after arthroscopic repair, particularly in older patients [35]. Ernstbrunner et al. found no significant difference in advanced OA between BR in the lateral position and open Latarjet procedures at a mean 13-year follow-up in patients over 40 years of age, provided there were no technical errors (anchor positioning or graft overhang) [36].

The limitations of the study are its retrospective design, without a control group with a nonoperative treatment, and the small size of the series. Although the size of the series is small (10 patients), the high follow-up rate (90%) and with a

mean follow-up of 6,8 years, allows us to present our results and our concerns about this type of fracture.

Conclusion

The open Latarjet procedure is an effective technique for stabilizing the shoulder in patients with large anterior glenoid rim fractures (> 20%). Although there is a high rate of glenohumeral osteoarthritis observed post-operatively, the procedure successfully prevents recurrent dislocations, leading to a high satisfaction rate. It remains challenging to determine whether the observed osteoarthritis was due to the initial trauma or the surgical procedure, except in cases where the graft was lateralized.

Open access statement

This is an open-access article distributed under the terms of the Creative Commons Attribution Licence for Commercial and Non-Commercial Purposes (**CC BY 4.0**, see https://creativecommons.org/licenses/by/4.0/), which allows free use, distribution, adaptation, and commercial use of a work, provided proper credit is given to the creator.

Source of funding

This research did not receive any specific grant from funding agencies in the public, commercial, or non-profit sectors for the preparation of this manuscript. No benefits in any form have been received from a commercial party related directly to the subject of the article. The Scientific Council of our clinic “Clinique des Cèdres, Grenoble, France” has approved the above project and its publication.

Conflicts of interest

Dr. Barth receive consultant fees for Arthrex, SBM and MoveUp and Royalties from MoveUp and SBM not related to this article. Dr. Saragaglia receive Royalties from X’NOV company not related to this article. Dr Martinel receive consultant fees for SBM not related to this article.

References

1. Zacchilli MA, Owens BD. Epidemiology of Shoulder Dislocations Presenting to Emergency Departments in the United States. 2010;92(3). DOI: 10.2106/JBJS.I.00450
2. Leroux T, Ogilvie-Harris D, Veillette C, Chahal J, Dwyer T, Khoshbin A, et al. The Epidemiology of Primary Anterior Shoulder Dislocations in Patients Aged 10 to 16 Years. Am J Sports Med. septiembre de 2015;43(9):2111-7. DOI: 10.1177/0363546515591996
3. Mazzocca AD, Cote MP, Solovyova O, Rizvi SHH, Mostofi A, Arciero RA. Traumatic Shoulder Instability Involving Anterior, Inferior, and Posterior Labral Injury: A Prospective Clinical Evaluation of Arthroscopic Repair of 270° Labral Tears. Am J Sports Med. agosto de 2011;39(8):1687-97. DOI: 10.1177/0363546511405449
4. Spatschil A, Landsiedl F, Anderl W, Imhoff A, Seiler H, Vassilev I, et al. Posttraumatic anterior-inferior instability of the shoulder: arthroscopic findings and clinical correlations. Arch Orthop Trauma Surg 126, 217–222 (2006) https://doi.org/10.1007/s00402-005-0006-4
5. Porcellini G, Campi F, Paladini P. Arthroscopic approach to acute bony Bankart lesion. Arthrosc J Arthrosc Relat Surg. September 2002;18(7):764-9. https://doi.org/10.1053/jars.2002.35266
6. Godin JA, Altintas B, Horan MP, Hussain ZB, Pogorzelski J, Fritz EM, et al. Midterm Results of the Bony Bankart Bridge Technique for the Treatment of Bony Bankart Lesions. Am J Sports Med. January 2019;47(1):158-64. DOI: 10.1177/0363546518808495
7. Millett PJ, Horan MP, Martetschläger F. The “Bony Bankart Bridge” Technique for Restoration of Anterior Shoulder Stability. Am J Sports Med. March 2013;41(3):608-14. DOI: 10.1177/0363546512472880
8. Frich LH, Larsen MS. How to deal with a glenoid fracture. EFORT Open Rev. May 2017;2(5):151-7. DOI: 10.1302/2058-5241.2.160011
9. Yamamoto N, Itoi E. Osseous Defects Seen in Patients with Anterior Shoulder Instability. Clin Orthop Surg. 2015;7(4):425. DOI: 10.4055/cios.2015.7.4.425
10. Pires RE, Giordano V, De Souza FSM, Labronici PJ. Current challenges and controversies in the management of scapular fractures: a review. Patient Saf Surg. December 2021;15(1):6. DOI: 10.1186/s13037-020-00281-3
11. Mercier N, Saragaglia D. Mini-Open Latarjet Procedure for Recurrent Anterior Shoulder Instability. Adv Orthop. 2011;2011:1-6. http://www.hindawi.com/journals/aorth/2011/656205/ DOI: 10.1155/2011/656205
12. Samilson RL, Prieto V. Dislocation arthropathy of the shoulder. J Bone Joint Surg Am. April 1983;65(4):456-60. DOI: 10.2106/00004623-198365040-00010
13. ALLAIN J, GOUTALLIER D, GLORION C. Long-Term Results of the Latarjet Procedure for the Treatment of Anterior Instability of the Shoulder*. JBJS. 1998;80(6). https://journals.lww.com/jbjsjournal/fulltext/1998/06000/l DOI: 10.2106/00004623-199806000-00008
14. Gordins V, Sansone M, Thorolfsson B, Möller M, Carling M, Olsson N. Incidence of bony Bankart lesions in Sweden: a study of 790 cases from the Swedish fracture register. J Orthop Surg [Internet]. September 2023;18(1):680. https://josr-online.biomedcentral.com/articles/10.1186/s13018-023-04173-x DOI: 10.1186/s13018-023-04173-x
15. Huston LJ, Wojtys EM. Neuromuscular Performance Characteristics in Elite Female Athletes. Am J Sports Med. July 1996; 24(4):427-36. https://journals.sagepub.com/doi/10.1177/036354659602 DOI: 10.1177/036354659602400405
16. Buckwalter JA, -Y. Woo SL. Age-Related Changes in Ligaments and Joint Capsules: Implications for Participation in Sports. Sports Med Arthrosc Rev. 1996;4(3). https://journals.lww.com/sportsmedarthro/fulltext/1996/0 DOI: 10.1097/00042752-199603000-00006

17. Scheibel M, Magosch P, Lichtenberg S, Habermeyer P. Open reconstruction of anterior glenoid rim fractures. Knee Surg Sports Traumatol Arthrosc. November 2004;12(6):568-73. http://link.springer.com/10.1007/s00167-004-0495-7 DOI: 10.1007/s00167-004-0495-7

18. Sugaya H, Kon Y, Tsuchiya A. Arthroscopic Repair of Glenoid Fractures Using Suture Anchors. Arthrosc J Arthrosc Relat Surg. May 2005;21(5):635.e1-635.e5. https://linkinghub.elsevier.com/retrieve/pii/S0749806305C DOI: 10.1016/j.arthro.2005.02.011

19. Tauber M, Moursy M, Eppel M, Koller H, Resch H. Arthroscopic screw fixation of large anterior glenoid fractures. Knee Surg Sports Traumatol Arthrosc. March 2008;16(3):326-32. http://link.springer.com/10.1007/s00167-007-0437-2 DOI: 10.1007/s00167-007-0437-2

20. Chen AZ, Greaves KM, deMeireles AJ, Fortney TA, Saltzman BM, Trofa DP. Clinical Outcomes of Arthroscopic Bony Bankart Repair for Anterior Instability of the Shoulder: A Systematic Review. Am J Sports Med. August 2023;51(10):2758-65. http://journals.sagepub.com/doi/10.1177/036354652210 DOI: 10.1177/03635465221094832

21. Giordano V, Pires RE, Labronici PJ, Vieira I, De Souza FS, Sassine TJ, et al. Open reduction and internal fixation of Ideberg type IA glenoid fractures: Tricks, pearls, and potential pitfalls based on a retrospective cohort of 33 patients focusing on the rehabilitation protocol. Eur J Orthop Surg Traumatol. September 2022;33(3):571-80. https://link.springer.com/10.1007/s00590-022-03389-7 DOI: 10.1007/s00590-022-03389-7

22. Bonnevialle N, Clavert P, Arboucalot M, Bahlau D, Bauer T, Ehlinger M. Contribution of arthroscopy in the treatment of anterior glenoid rim fractures: a comparison with open surgery. J Shoulder Elbow Surg. January 2019;28(1):42-7. https://linkinghub.elsevier.com/retrieve/pii/S10582746183 DOI: 10.1016/j.jse.2018.08.026

23. Wafaisade A, Kappel P, Pfeiffer TR, Lambert C, Banerjee M. Arthroscopic Screw Fixation Technique for Transverse Glenoid Fractures. Arthrosc Tech. November 2021;10(11):e2495-9. https://linkinghub.elsevier.com/retrieve/pii/S2212628721C DOI: 10.1016/j.eats.2021.07.021

24. Avramidis G, Brilakis E, Deligeorgis A, Antonogiannakis E. All-Arthroscopic Treatment of Glenoid Rim Fractures. Arthrosc Tech. October 2019;8(10):e1121-4. https://linkinghub.elsevier.com/retrieve/pii/S2212628719 DOI: 10.1016/j.eats.2019.06.001

25. Nakagawa S, Hirose T, Tachibana Y, Iuchi R, Mae T. Postoperative Recurrence of Instability Due to New Anterior Glenoid Rim Fractures After Arthroscopic Bankart Repair. Am J Sports Med. October 2017;45(12):2840-8. http://journals.sagepub.com/doi/10.1177/036354651771 DOI: 10.1177/0363546517714476

26. Woolnough T, Shah A, Sheean AJ, Lesniak BP, Wong I, De Sa D. "Postage Stamp" Fractures: A Systematic Review of Patient and Suture Anchor Profiles Causing Anterior Glenoid Rim Fractures After Bankart Repair. Arthrosc J Arthrosc Relat Surg. August 2019;35(8):2501-2508.e2. https://linkinghub.elsevier.com/retrieve/pii/S0749806319 DOI: 10.1016/j.arthro.2019.03.010

27. Cole PA, Freeman G, Dubin JR. Scapula fractures. Curr Rev Musculoskelet Med. March 2013;6(1):79-87. http://link.springer.com/10.1007/s12178-012-9151-x DOI: 10.1007/s12178-012-9151-x

28. Adam F. Surgical treatment of displaced fractures of the glenoid cavity. Int Orthop. June 2002;26(3):150-3. http://link.springer.com/10.1007/s00264-002-0342-8 DOI: 10.1007/s00264-002-0342-8

29. Pfister G, Murison JC, Sabate-Ferris A, Danis J, De l'Escalopier N, Mathieu L. Open Screw Fixation of Large Anterior Glenoid Rim Fractures Using a Deltopectoral Approach With Subscapularis Splitting. Tech Hand Up Extrem Surg. September 2022 ;26(3):188-92. https://journals.lww.com/10.1097/BTH.000000000000038 DOI: 10.1097/BTH.0000000000000383

30. Pires RE, Giordano V, De Souza FSM, Labronici PJ. Current challenges and controversies in the management of scapular fractures: a review. Patient Saf Surg. December 2021;15(1):6. https://pssjournal.biomedcentral.com/articles/10.1186/s1020-00281-3 DOI: 10.1186/s13037-020-00281-3

31. Raiss P, Baumann F, Akbar M, Rickert M, Loew M. Open screw fixation of large anterior glenoid rim fractures: mid- and long-term results in 29 patients. Knee Surg Sports Traumatol Arthrosc. February 2009;17(2):195-203. http://link.springer.com/10.1007/s00167-008-0677-9 DOI: 10.1007/s00167-008-0677-9

32. Yian EH, Ramappa AJ, Arneberg O, Gerber C. The constant score in normal shoulders. J Shoulder Elbow Surg. March 2005;14(2):128-33. https://linkinghub.elsevier.com/retrieve/pii/S1058274604C DOI: 10.1016/j.jse.2004.06.003

33. Pape M, Blaas LS, Yuan JZ, De Priester JA, Bruinenberg AR, Buijs N, et al. Coracoid osteotomy in anterior fracture-dislocation with concomitant bony Bankart: a way to safely retrieve the humeral head and provide instant stability (acute Latarjet). JSES Rev Rep Tech. February 2022;2(1):40-5. https://linkinghub.elsevier.com/retrieve/pii/S2666391210 DOI: 10.1016/j.xjht.2021.12.003

34. Hovelius L, Sandström B, Sundgren K, Saebö M. One hundred eighteen Bristow-Latarjet repairs for recurrent anterior dislocation of the shoulder prospectively followed for fifteen years: Study I—clinical results. J Shoulder Elbow Surg. September 2004;13(5):509-16. https://linkinghub.elsevier.com/retrieve/pii/S1058274604C DOI: 10.1016/j.jse.2004.03.004

35. Boehm E, Keck A, Krueger D, Scheibel M. Arthroscopic repair of anteroinferior glenoid rim fractures: mean 10-year clinical and radiologic results. J Shoulder Elbow Surg. December 2024;33(12):2893-8. https://linkinghub.elsevier.com/retrieve/pii/S1058274624C DOI: 10.1016/j.jse.2024.05.014

36. Ernstbrunner L, De Nard B, Olthof M, Beeler S, Bouaicha S, Gerber C, et al. Long-term Results of the Arthroscopic Bankart Repair for Recurrent Anterior Shoulder Instability in Patients Older Than 40 Years: A Comparison With the Open Latarjet Procedure. Am J Sports Med. julio de 2020;48(9):2090-6. DOI: 10.1177/0363546520923441