Assessing Tendon-to-Bone Healing in Arthroscopic Subscapularis Augmentation for Anterior Shoulder Instability: A second look arthroscopy study

Nikolaos Platon Sachinis [1] *, Emmanouil Brilakis [2], Geroge Gatos [2], Angelos Trelopoulos [2], Ioannis Pantekidis [2], Emmanouil Antonogiannakis [2]

(*) corresponding author: nick.sachinis@gmail.com
1. First Orthopaedic Department of Aristotle University of Thessaloniki, "Georgios Papanikolaou" Hospital, Thessaloniki, Greece
2. Third Orthopaedic Department, Hygeia Hospital, Athens, Greece

Background: Recurrent anterior shoulder instability with subcritical bone loss is a significant clinical challenge, particularly in active individuals. Arthroscopic Subscapularis Augmentation (ASA) has emerged as an adjunct to the classic Bankart repair to enhance stability.

Purpose: This study aimed to evaluate the tendon-to-bone healing rate of the subscapularis tendon following ASA using second-look arthroscopy.

Methods: This prospective cohort study included 21 patients undergoing ASA to augment Bankart repair with or without a bone block procedure. All procedures were performed arthroscopically. Six months postoperatively, second-look arthroscopy was performed to assess the healing and integration of the subscapularis tendon onto the glenoid. The integrity of the repair was evaluated both visually and using a probe to assess fixation. Interim analyses were planned after the 10th and 20th patients to ensure robust outcomes and enable early study termination if indicated. Statistical analyses were performed to establish confidence in the observed outcome, which was the healing rate of the subscapularis tendon to the glenoid.

Results: Second-look arthroscopy demonstrated evidence of subscapularis tendon healing to the glenoid in all patients. Probe testing confirmed secure fixation in all cases. Interim analyses confirmed a 100% healing rate after the 20th patient, leading to early study termination. No evidence of inflammation or arthritic changes was observed during follow-up. Post hoc analysis reinforced the reliability of the findings, with a 95% confidence interval of 0.916 to 1.000.

Conclusion: Arthroscopic subscapularis augmentation demonstrates secure fixation of the subscapularis tendon to the glenoid as assessed by second-look arthroscopy and probe testing. While these results support the technique's potential, longer follow-up studies and additional imaging modalities such as MRI are needed to further evaluate healing and long-term clinical outcomes.

What this study adds: This is the first study to directly confirm that the subscapularis tendon heals securely to the glenoid after Arthroscopic Subscapularis Augmentation (ASA). Using second-look arthroscopy and probe testing, we showed reliable tendon-to-bone integration at 6 months.

How this study might affect research, practice or policy: Our findings give surgeons evidence that ASA is a biologically sound option when Bankart repair alone may not be enough, such as in cases of hyperlaxity or capsular insufficiency. This could encourage wider use of ASA as a less invasive alternative to bone block procedures. For research, the study provides a baseline for comparing second look healing of ASA with imaging techniques like MRI in the future.

Study Design: Therapeutic study

Level of Evidence: Level IV

Keywords: Anterior shoulder instability; Arthroscopic Subscapularis Augmentation; ASA; Bankart repair; Tendon-to-bone healing; Second-look arthroscopy

Abbreviations: DAS: Dynamic Anterior Stabilization, ASA: Arthroscopic Subscapularis Augmentation, ROM: Range of Motion

https://doi.org/10.70885/hmsj.2025.08.002

Introduction

Recurrent anterior shoulder instability with subcritical bone loss remains a major challenge in orthopaedic surgery. Traditional Bankart repair, although widely used, is associated with high recurrence rates, particularly in young individuals, athletes, and individuals with hyperlaxity [1]. To address this issue, various augmentation techniques have been developed, including Dynamic Anterior Stabilization (DAS) [2] and Remplissage [3][4].

Maiotti et al. introduced an arthroscopic technique in 2013 for augmenting the classic Bankart repair using the upper third of the articular portion of the subscapularis tendon [5]. This technique's name is ASA, which is extracted from the initials of the Arthroscopic Subscapularis Augmentation. It involves the tenodesis of the subscapularis tendon to the anterior glenoid rim using knotless or knotted soft anchors loaded with a suture or tape. This technique decreases the recurrence rate of the classic Bankart repair without a significant clinical reduction of the shoulder range of motion (ROM) [5][6][7][8].

The success of this procedure also depends on the postoperative confirmation of tissue healing and integration. The latter may be confirmed by second-look arthroscopy, which has been employed in the past to establish the effectiveness of a procedure [9].

In our study, we aim to evaluate the healing rate of the subscapularis tendon using second-look arthroscopy in patients undergoing ASA, either augmenting the classic arthroscopic Bankart repair or in addition to an arthroscopic Eden-Hybinette procedure; the latter augmentation was performed when increased laxity or insufficiency of the capsule and anterior soft tissue structures was observed [10]. This prospective cohort study seeks to evaluate the healing rate of the subscapularis tendon to the glenoid using second-look arthroscopy with both visual inspection and probe testing, thus contributing to the evidence supporting this approach.

Material & Methods

Study design

The study was designed as a prospective cohort to evaluate the healing rate of the subscapularis tendon in patients undergoing ASA along with a Bankart repair +/- a bone block procedure via a second-look arthroscopy (**Figure 1**). It was conducted following the Declaration of Helsinki and has been approved by the hospital's scientific committee (36910). All patients included provided written consent regarding any intervention reported. In this study, patients who met all inclusion and none of the exclusion criteria were enrolled.

Participants

From January 2021 to December 2022, 23 consequent patients with recurrent anterior shoulder dislocation underwent ASA augmenting an arthroscopic Bankart repair or an arthroscopic Eden-Hybinette procedure in our hospital. Inclusion criteria, apart from the initial procedure, included patients under 65 years old who had completed the rehabilitation protocol without significant deviations. Exclusion criteria were site infection after the initial operation and technical inability to check the healing status of the subscapularis onto the glenoid during the second look arthroscopy.

Initial Surgical Procedure

All patients were treated using the same surgical technique. The procedure was conducted arthroscopically, with the patient positioned in the lateral decubitus position under general anaesthesia, with arm traction applied at 3kg. Standard portals were used: posterior, anterior, and anterosuperior. An anterior inferior portal was created over the superior border of the subscapularis tendon to facilitate direct access for suture-passing instruments. The anterosuperior portal served as the viewing portal.

According to the indications, a standard Bankart repair or an arthroscopic Eden-Hybinette procedure was performed as the primary operation. The ASA technique was added in cases with clinical hyperlaxity or anterior capsular insufficiency, as also described in the study by Russo et al. [10]. After completing this stage, an additional all-suture anchor (Y-knot ConMed, Largo, FL, USA, or Suturefix Smith & Nephew, Watford, UK) was placed between the 2 and 3 o'clock positions on the anterior glenoid rim (for a right shoulder). The arm traction was then released, and an assistant held the arm in 30 degrees of abduction and maximum external rotation to prevent overtightening of the subscapularis tendon. The tendon was pierced about 5mm below its superior border at the glenoid level. The suture limb passing through the subscapularis was retrieved and carefully managed through the anterior portal.

The Nice knot technique, initially described by Boileau et al., was employed [11]. The procedure concluded with checking the centralisation of the humeral head with the glenoid and ensuring the stability of the glenohumeral joint via the anterosuperior portal. The arm was then placed at 90 degrees of abduction and 90 degrees of external rotation to confirm an unrestricted range of motion before the standard closure of the arthroscopic portals

Postoperative protocol

Following the surgery, the operated shoulder was immobilised in a simple sling for four weeks. During the first week, patients could engage in daily activities if shoulder movements were pain-free and restricted to specific limits: 90 degrees of forward flexion, 10 degrees of external rotation, and internal rotation in front of the body. At three weeks postoperatively, patients began active-assisted exercises, transitioning to fully active exercises based on their progress. Strengthening exercises were introduced after the range of motion was restored and no sooner than six weeks post-surgery.

Patients were cleared to participate in competitive sports between 4 to 6 months postoperatively. This timeline depended on the patient's progress in their personalised rehabilitation program, the type of sport, and the competition level.

Second look arthroscopy

At the 6-month postoperative follow-up visit, each patient underwent a diagnostic needle shoulder arthroscopy using a 1.9mm wide nanoscope with a 2.4mm wide sheath (Arthrex, Naples, FL, USA) after obtaining written consent. The arthroscopy was performed with the patient in the beach chair position, under local anaesthesia, following proper sterilisation, prepping, and draping. A clear view, from one posterior portal of the repair of the upper 5mm of the subscapularis to the glenoid was obtained in all cases. A probe from an anterior portal assessed the subscapularis tendon's fixation to the glenoid by pulling/stretching its upper portion during external rotation with the arm in neutral and abduction positions. If a gap would be observed between the

tendon and the bone during the described procedure, or if the subscapularis was identified as torn at or near the anchor site, that would indicate a lack of tendon healing at the anchor location. In addition to assessing the repair status and healing of the subscapularis to the glenoid, any presence of arthritic or inflammatory changes was also noted.

Statistics

An a priori power analysis was done to determine the required sample size. To our knowledge, no previous study has established an approximate tendon-to-bone healing rate frequency on such or similar occasions. Assuming a conservative estimated success rate of 80%, significance (α) of 0.05, and power of 80%, the power analysis indicated a sample size of 32 patients. Accounting for a 10% loss on follow-up, we aimed to recruit 35 patients. Two interim statistical studies were arranged after the 10th and the 20th patient to measure the desired patient outcomes while also being efficient with resources.

The Pocock boundary methods were used to adjust the significance for each interim analysis, allowing for early termination of the trial if solid evidence of subscapularis healing was found. The study was terminated early after the second analysis of 20 patients, all showing successful healing of the subscapularis tendon. Data from the 21st patient, already available during the second interim analysis, was included in the final analysis. This inclusion did not alter the overall study conclusions but supported the observed outcomes.
Subsequently, a post hoc study was conducted to assess the reliability of the study at the point of early stopping. The Wilson score interval with continuity correction was used to calculate the 95% confidence interval for the reported success rate.

Results

Thirty-five patients were initially planned for inclusion in this study, adding a dropout rate of 10% to the a priori calculation of 32 patients. During the recruitment period, 23 patients were enrolled. However, two patients declined to undergo the second-look arthroscopy, resulting in a final cohort of 21 patients. The demographic characteristics of these patients are presented in **Table** 1.

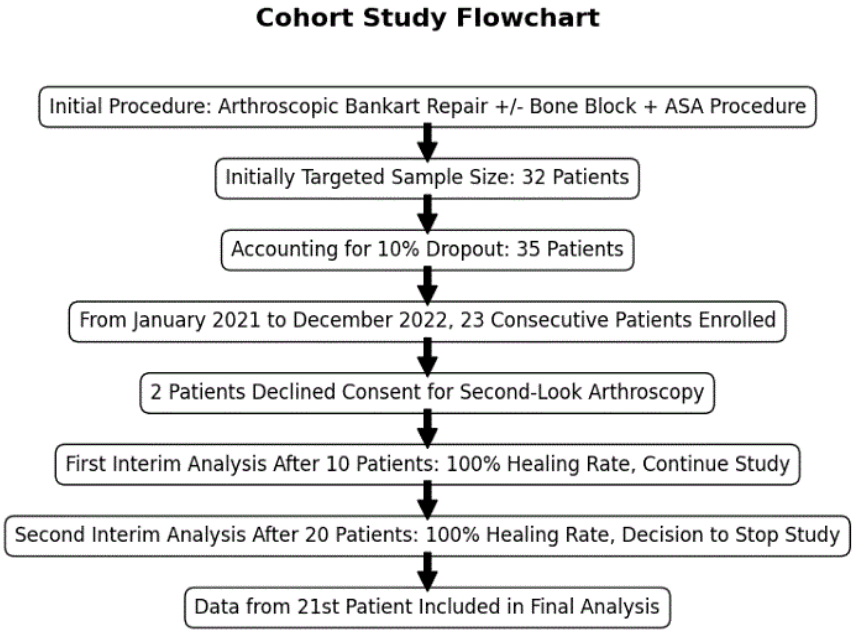

Figure 1. Flowchart of this prospective cohort study. ASA: Arthroscopic Subscapularis Augmentation

Second-look arthroscopy by visual inspection and probe testing revealed subscapularis tendon adherence to the glenoid in all 21 patients (**Figure 2**). In addition to the repair assessment, no arthritic changes were observed in any patients.

Interim analyses were planned after 10 and 20 patients. The first interim analysis involving ten patients showed a 100% healing rate of the subscapularis to the glenoid. The Z-score for this analysis was calculated as 1.58, and based on these results, the study was continued. The second interim test, conducted with 20 patients and a reported 100% healing rate, provided a Z-score of 2.25. The Pocock boundary critical value for two planned interim analyses was 2.24. As the Z-score met this critical value, the study was stopped early based on the observed data and clinical judgment. Data from the 21st patient, already available during the interim analysis, was included in the final analysis.

A post hoc Wilson test was conducted, resulting in a 95% confidence interval for the healing rate of approximately 0.916 to 1.0000. This supports the observed effectiveness of this technique, indicating high confidence in the results obtained from the interim analyses.

There were no other complications during the second look arthroscopy, apart from a patient who experienced a superficial skin infection at the portal site that resolved within 7 days by taking oral cefuroxime 500mg twice daily. Patients reported no loss of ROM or persistent pain, even at two weeks post-op. They were advised to resume daily activities as tolerated and return to sports after two weeks.

Table 1. Demographic and Baseline Characteristics of Patients (N=21)

Characteristics	Mean ± SD	Range
Age (years)	28.5 ± 6.3	20-45
Sex (Male/Female)	15/6	-
Duration of Symptoms (months)	14.2 ± 5.7	6-30
Number of Dislocations	3.4 ± 2.1	1-10
Dominant Shoulder (Right/Left)	17/4	-
Procedure involving a bone block/ no bone block	12/9	-

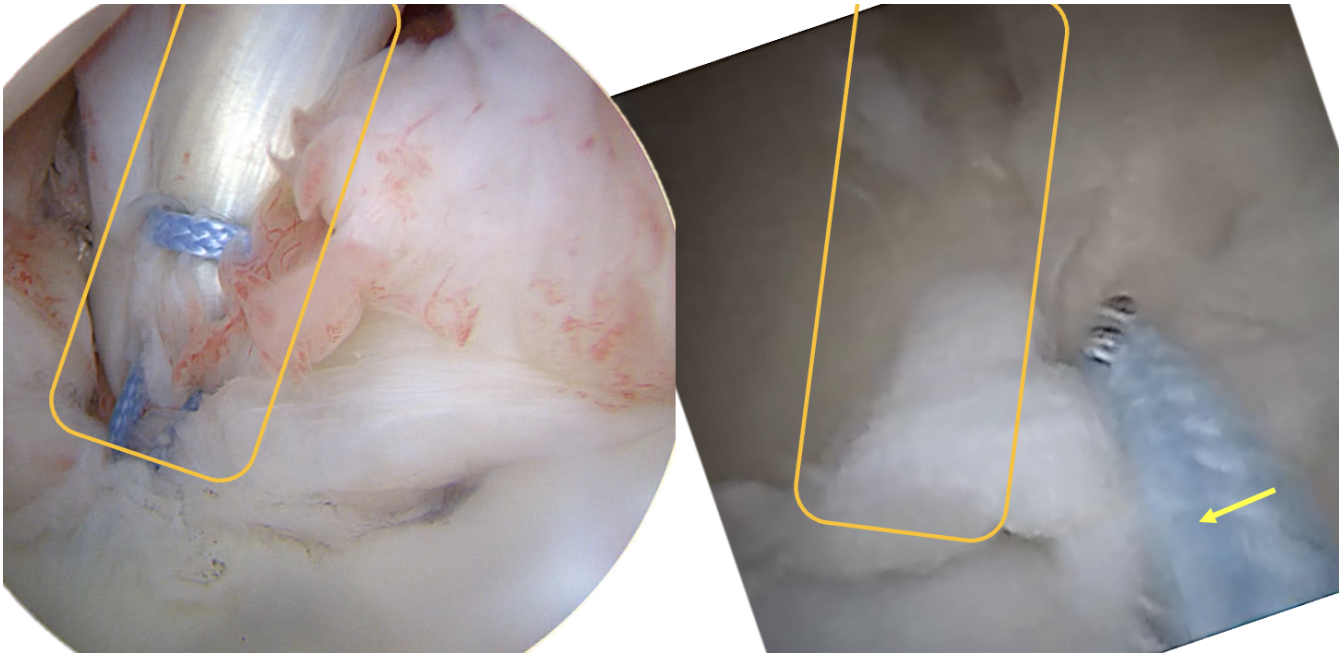

Figure 2. Operative (Left) and 6-month postoperative (Right) scoping images of the left shoulder of a 23-year-old patient with recurrent anterior instability. The glenoid is at the bottom of the images, and the subscapularis (marked with a yellow rectangle) is on the top. On the post-op magnified image, the tail of a knot is also viewed and marked with a yellow arrow. Probe testing was performed during second-look arthroscopy, confirming secure tendon fixation to the glenoid. The postoperative image provides a visual reference for the healed tendon-to-bone attachment but does not replace histological or MRI confirmation.

Discussion

Our study investigated the integrity of the subscapularis tendon attachment to the glenoid in 21 patients who underwent Arthroscopic Subscapularis Augmentation combined with Bankart repair, with or without a bone block procedure. Six months post-surgery, second-look arthroscopy showed healing of the subscapularis tendon to the glenoid in all patients. No signs of arthritis or inflammation were also seen during this second procedure. These results indicate that the ASA technique is highly effective in achieving tendon-to-bone integration.

The ASA procedure was introduced by Maiotti et al. in 2013 [5]. In this technique, the subscapularis tendon is fixed to the anterior rim of the glenoid using a high-strength tape and a knotless anchor. This technique is aimed at stabilising the shoulder while maintaining range of motion. In a later study involving 25 athletes, Maiotti et al. reported a 92% success rate in restoring joint stability without recurrences, with only a 5-degree loss in external rotation, which was not clinically significant [7].

The effectiveness of the ASA technique was further evidenced by Hussein et al., who evaluated 30 patients with recurrent anterior shoulder dislocation [12]. They found a recurrence rate of just 6% and minimal complications following the combined ASA and Bankart repair procedure. Additionally, Russo et al. showed that ASA is as effective as the open Latarjet procedure for treating recurrent anterior shoulder instability with moderate glenoid bone loss, providing a less invasive option with comparable results [13].

Second-look arthroscopy has been valuable in other studies to confirm the success of surgical procedures. Nakagawa et al. used second-look arthroscopy to assess the integrity of rotator cuff repairs in partial-thickness tears [9]. They found complete tendon continuity in 80% of patients with repairs of full-thickness converted tears, compared to only 30% in those with trans-tendon repairs. Similarly, Siebold et al. reported that 91.3% of cartilage defects showed normal or nearly

normal regeneration after arthroscopic autologous chondrocyte implantation checked by direct vision after second-look arthroscopy [14].

Our results align with second-look arthroscopy studies showing early tendon-to-bone healing. Nakagawa et al. [9] reported 80% tendon integrity after rotator cuff repair at similar follow-up, and Siebold et al. [14] observed 91% healing in chondral repairs, supporting the validity of arthroscopic assessment at 6 months. For posterior remplissage, studies such as Brilakis et al. [3] demonstrated good clinical outcomes, though tendon integration was not directly assessed. Anterior remplissage (ASA) has also shown promising results but data on confirmed subscapularis healing are limited [7][8]. To our knowledge, this is the first study to document subscapularis-to-glenoid healing after ASA under direct arthroscopic visualization. While six months may not capture full biological remodeling, it provides a reliable window for assessing fixation integrity without disturbing healing tissues.

While our study's findings are promising, the 100% healing rate observed may specifically apply to the modified ASA technique we used; other variations of the ASA technique might yield different results. Healing was also assessed arthroscopically without additional imaging such as MRI, which could provide further confirmation. Further research is needed to determine if these findings can be generalised to other modified ASA procedures. We used second-look arthroscopy to directly assess tendon healing, as it allows real-time visual and mechanical evaluation of the repair. While MRI, especially MR arthrography, can provide structural information, it may not reliably distinguish true tendon integration from scar tissue at this stage. It also lacks dynamic assessment and would have added cost and complexity. Future studies may explore combining MRI with arthroscopic findings to validate non-invasive methods.

Also, since this study was specifically designed to check for the successful initial healing of the subscapularis to the glenoid, the longevity of this repair and endurance cannot be established from our results. Long term evaluation is needed to determine whether this translates to sustained improved clinical outcomes and reduced re-dislocation rates. Also, while no signs of arthritic changes were noted, longer follow-up and imaging studies would be required to assess this. Additionally, the early termination of the study based on interim analysis may have introduced selection bias.

Conclusion

Our study shows that this ASA technique achieves healing and secure integration of the subscapularis tendon to the anterior glenoid, as assessed by second look arthroscopy and probe testing. These results support the technique's potential in managing recurrent anterior shoulder instability. Future studies with larger sample sizes, different surgical techniques, and imaging confirmation are warranted to confirm these results and assess long-term outcomes.

Open access statement

This is an open-access article distributed under the terms of the Creative Commons Attribution Licence for Commercial and Non-Commercial Purposes (**CC BY 4.0**, see https://creativecommons.org/licenses/by/4.0/), which allows free use, distribution, adaptation, and commercial use of a work, provided proper credit is given to the creator.

Source of funding

This study received no external funding.

Conflicts of interest

The authors declare no conflicts of interest.

References

1. Balg F and Boileau P. The instability severity index score. A simple pre-operative score to select patients for arthroscopic or open shoulder stabilisation. J Bone Joint Surg Br 2007; 89: 1470-1477. 2007/11/14. DOI: 10.1302/0301-620X.89B11.18962.
2. de Campos Azevedo CI and Angelo AC. Dynamic Anterior Stabilization of the Shoulder: Onlay Biceps Transfer to the Anterior Glenoid Using the Double Double-Pulley Technique. Arthrosc Tech 2023; 12: e1097-e1106. 2023/08/03. DOI: 10.1016/j.eats.2023.02.048.
3. Brilakis E, Avramidis G, Malahias MA, et al. Long-term outcome of arthroscopic remplissage in addition to the classic Bankart repair for the management of recurrent anterior shoulder instability with engaging Hill-Sachs lesions. Knee Surg Sports Traumatol Arthrosc 2019; 27: 305-313. 2018/10/31. DOI: 10.1007/s00167-018-5261-3.
4. Yamamoto N, Muraki T, An KN, et al. The stabilizing mechanism of the Latarjet procedure: a cadaveric study. J Bone Joint Surg Am 2013; 95: 1390-1397. 2013/08/09. DOI: 10.2106/JBJS.L.00777.
5. Maiotti M and Massoni C. Arthroscopic augmentation with subscapularis tendon in anterior shoulder instability with capsulolabral deficiency. Arthrosc Tech 2013; 2: e303-310. 2013/11/23. DOI: 10.1016/j.eats.2013.04.005.
6. Maiotti M, Massoni C, Russo R, et al. Arthroscopic Subscapularis Augmentation of Bankart Repair in Chronic Anterior Shoulder Instability With Bone Loss Less Than 25% and Capsular Deficiency: Clinical Multicenter Study. Arthroscopy 2017; 33: 902-909. 2016/11/24. DOI: 10.1016/j.arthro.2016.09.008.
7. Maiotti M, Russo R, Zanini A, et al. Bankart Repair With Subscapularis Augmentation in Athletes With Shoulder Hyperlaxity. Arthroscopy 2021; 37: 2055-2062. 2021/02/14. DOI: 10.1016/j.arthro.2021.01.062.
8. Maiotti M, Russo R, Zanini A, et al. Arthroscopic Bankart repair and subscapularis augmentation: an alternative technique treating anterior shoulder instability with bone loss. J Shoulder Elbow Surg 2016; 25: 898-906. 2015/11/29. DOI: 10.1016/j.jse.2015.09.025.
9. Nakagawa S, Mizuno N, Sahara W, et al. Insufficient integrity of partial articular surface tendon avulsion lesions after arthroscopic trans-tendon repair: Comparison with integrity after arthroscopic repair after conversion to a full thickness tear. J Orthop Sci 2020; 25: 992-998. 20200228. DOI: 10.1016/j.jos.2020.01.014.
10. Russo R, Maiotti M, Taverna E, et al. Arthroscopic Bone Graft Procedure Combined With Arthroscopic Subscapularis Augmentation for Recurrent Anterior Instability With Glenoid Bone Defect. Arthrosc Tech 2018; 7: e623-e632. 2018/06/30. DOI: 10.1016/j.eats.2018.02.009.
11. Boileau P, Alami G, Rumian A, et al. The Doubled-Suture Nice Knot. Orthopedics 2017; 40: e382-e386. 2016/12/13. DOI: 10.3928/01477447-20161202-05.

12. Hussein IA, Hassan MA-A and Nematallah SA. Arthroscopic Bankart Repair with Subscapularis Augmentation in The Treatment of Recurrent Anterior Shoulder Instability with Bone Loss. The Egyptian Journal of Hospital Medicine 2019; 74: 1473-1480. DOI: 10.21608/ejhm.2019.27417.
13. Russo R, Della Rotonda G, Cautiero F, et al. Arthroscopic Bankart repair associated with subscapularis augmentation (ASA) versus open Latarjet to treat recurrent anterior shoulder instability with moderate glenoid bone loss: clinical comparison of two series. Musculoskelet Surg 2017; 101: 75-83. 20161221. DOI: 10.1007/s12306-016-0446-8.
14. Siebold R, Karidakis G, Feil S, et al. Second-look assessment after all-arthroscopic autologous chondrocyte implantation with spheroides at the knee joint. Knee Surg Sports Traumatol Arthrosc 2016; 24: 1678-1685. 20151224. DOI: 10.1007/s00167-015-3822-2.